Role of Neuroimaging in Muscle and Peripheral Nerve Diseases

Essay

Submitted for Partial Fulfillment of Master Degree
In **Neurology & Psychiatry**

Presented By

Mona Ahmed Taha
M.B.BCh

Under Supervision of

Prof.Dr. Mohamed Yasser Mohamed Metwaly
Professor of Neurolgy
Faculty ofMedicine- Ain Shams University

www.yassermetwally.com

Contents

Introduction 3

Classification of muscle and peripheral nerve diseases **8**

Pathology and Pathogenesis. **17**

Neuroimaging of muscle dystrophy **70**

Neuroimaging of inflammatory myopathies **91**

Neuroimaging of congenital myopathies **97**

Neuroimaging of peripheral nerve diseases **106**

Discussion **133**

Recommendations **140**

Summary **142**

References **153**

Introduction

Imaging of nerve and muscle is being used with an increasing frequency in the evaluation of patients with neuromuscular disorders ***(Grant et al., 2002).***

Plain x-rays have limited roles in imaging patients with muscle disease. An exception is identifying calcinosis in patients with myositis ***(Scott and Kingsley, 2004).***

Although both computerized axial tomography (CT) and ultrasound have been used, magnetic resonance imaging (MRI) is currently the imaging modality of choice in most circumstances ***(Anthony and James, 2008).***

Ultrasonography is of potential value as a diagnostic tool in that it is readily available, relatively inexpensive quick and painless ***(Walker et al., 2004).***

It is limited by the specificity of the changes it may demonstrate and its ability to assess deep structures or those in an obese population. It is capable of detecting altered echogenicity within muscle indicative of pathology as well as the existence and pattern of muscle atrophy or hypertrophy. Arguably, it is a diagnostic tool best applied to children and/or to identify an ideal muscle to biopsy ***(Halford Graves et al., 2000).***

Ultrasound has been used to identify nerve transaction and has demonstrated an89% sensitivity and 95% specificity under experimental conditions ***(Cartwright et al., 2007).***

The role of CT in neuromuscular disease has been in large part, usurped by MRI except in those who cannot have or tolerate MRI due to size, claustrophobia, or metallic implants. CT can differentiate nerve from muscle disease, not only based on the pattern of muscular involvement but based on the basis of X-ray attenuation changes within individual muscles as well. CT has been demonstrated to be 85% sensitive in detecting neuromuscular pathology, using muscle histology as the comparative gold standard ***(Anthony and James, 2008).***

MRI has numerous potential roles in the assessment of muscle disease ***(Scott and Kingsley, 2004).***

MR imaging with its multiplanar capabilities and high-contrast resolution has a high level of accuracy in characterising elastofibroma dorsi and may avoid the need for biopsy or surgical operation ***(Faccioli et al., 2009).***

Although most muscle injuries in the athlete are diagnosed clinically, MR imaging is an excellent noninvasive diagnostic adjunct to clinical examination, which allows the site and severity of muscle injury to be assessed accurately, influencing therapy and overall outcome. There has been a rapid expansion in the clinical use of MR imaging during the

past decade. MR imaging conveys unparalleled anatomic resolution and high sensitivity in the detection of acute and chronic muscle abnormalities ***(Shelly et al., 2009).***

In suspected myositis, muscle imaging should be strongly considered prior to obtaining a muscle biopsy. Future research should prospectively study the use of muscle imaging in the evaluation of treatment response and muscle function ***(Walker et al., 2008).***

Muscle MRI is an effective instrument in helping to diagnose pediatric myopathies of unknown aetiology. It may facilitate muscle biopsy and serves to control therapeutical effects and disease course. Furthermore, muscle MRI may be applicated even to children of less than 4 years of age without sedation ***(Peters et al., 2008).***

MRI has a number of beneficial applications in nerve disease as well; it has been reported to be occasionally beneficial in less frequent and at times controversial mononeuropathies including thoracicoutlet, piriformis syndromes, and tarsal tunnel syndrome, as well as posterior interosseous and peroneal neuropathies ***(Grant et al., 2002).***

MR imaging could be used to help predict the degree of nerve damage and monitor the process of nerve recovery in acute peripheral nerve traction injury ***(Shen et al., 2010).***

An imaging with a magnetic resonance tomography may be used in the diagnosis of atypical cases of carpal tunnel syndrome ***(Gautschi et al., 2010).***

MRI is capable of identifying areas of presumed inflammation, edema, and demyelination in the acquired inflammatory demyelinating neuropathies ***(Van et al., 2000).***

Aim of the Study

This essay aims to discuss the role of neuroimaging in diagnosis of muscle and peripheral nerve diseases.

Classification of Muscle and Peripheral Nerve Diseases

Peripheral neuropathy

- Introduction:

Peripheral neuropathy is a general term for disorders affecting peripheral nerves. The peripheral nervous system (PNS) involves all nerves lying outside the spinal cord and brainstem except the olfactory and optic nerves, which are extensions of the central nervous system (CNS) itself. All peripheral nerve axons are invested either with a wrapping of myelin made by Schwann cells (myelinated nerves) or by cytoplasm of Schwann cells (unmyelinated nerves) ***(Larry et al., 2005).***

PNS is composed of multiple cell types and elements that subserve diverse motor, sensory, and autonomic functions. The clinical manifestations of neuropathies depend on the severity, distribution, and functions affected ***(Lewis et al., 2010).***

Classification:

Peripheral neuropathy can be classified using several different criteria. They are often categorized in terms of the anatomy affected, the pathophysiologic process, their temporal development, and functional outcome ***(John et al., 2007).***

Anatomic Classification:

The major anatomic patterns of peripheral nerve disease can be distinguished by the clinical presentation—mononeuropathy, multiple mononeuropathy, and polyneuropathy.

Mononeuropathies occur when there is damage to a single peripheral nerve or root. This is seen with local entrapment from causes such as trauma (acute or chronic), tumor infiltration, or infarction.

Multiple mononeuropathies (mononeuropathy multiplex) occur when several nerves are individually affected by a disease process. Involvement is usually asymmetric and noncontiguous. They are much less common than other peripheral neuropathies and are more difficult to recognize and treat. Multiple mononeuropathies are usually seen with systemic diseases such as vasculitis, diabetes, and rheumatoid arthritis.

Polyneuropathies occur in a symmetric, diffuse, bilateral pattern. They produce a characteristic stocking-glove pattern of sensory changes. However, most polyneuropathies affect both sensory and motor nerves. Some can affect peripheral autonomic nerves. Many common peripheral neuropathies fall into this category ***(Sabin et al., 1993).***

Pathophysiologic Classification:

Based on the primary site of involvement, peripheral neuropathies can be classified as neuronopathies, axonal

neuropathies, and myelinopathies. Electrodiagnostic studies can help define this in a clinical setting.

Neuronopathies result from damage to the sensory cell bodies in the dorsal root ganglia or motor neuron cell bodies in the spinal cord. Their location in the CNS usually results in a degenerative process that produces incomplete recovery. Diseases that specifically affect the motor neuron cell bodies in the CNS are usually not categorized as peripheral neuropathies.

Axonal neuropathies occur when damage occurs at the level of the axon. When the axon is disrupted (e.g., by trauma), the axon and distal myelin sheath may degenerate distal to the site of injury (wallerian degeneration). In toxic or metabolic injuries, when the distal axon is injured and myelin degeneration spreads proximally, it is known as dying back neuropathy. With the dying back process, the longer nerves tend to be affected earlier and more severely.

Myelinopathies (demyelinating neuropathies) result from a process affecting primarily the myelin sheath. They can result from acute or chronic conditions. Examples of these include acute (Guillain-Barrésyndrome [GBS]) or chronic inflammatory demyelinating polyradiculoneuropathies (CIDPs) and certain hereditary neuropathies ***(John et al., 2007).***

Temporal Classification:

Acute peripheral neuropathies develop over a few days. When motor signs are predominant, GBS should be suspected first. Vasculitic or toxic processes can also present acutely. A subacute presentation may be seen in toxic, inflammatory, infiltrative, or carcinomatous processes that develop over weeks. A chronic-onset neuropathy may develop gradually and progress over months to years, as is the case in metabolic or hereditary neuropathies. Peripheral neuropathies may also have a relapsing course (Table 1).

Table (1): Neuropathies Classified by Temporal Presentation

Acute Onset (within days)	Subacute Onset (weeks to months)	Chronic Course (months to years)	Relapsing
GBS Vasculitis Porphyria Diphtheria Thallium toxicity Ischemia Penetrating trauma Rheumatoid arthritis Diabetic plexopathy or cranial neuropathy Acute nerve compression Polyarteritis nodosa Burns Iatrogenic (e.g., improper injection techniques)	Most toxins Most drugs Nutritional deficiencies Abnormal metabolic state Diabetic plexopathy Neoplasms Uremia	CIDP Alcohol Diabetes Hereditary neuropathies	GBS HIV Porphyria Refsum's disease CIDP

HIV : human immunodeficiency virus. ***(John et al., 2007)***

Classification of inherited neuropathies:

The current classification system of inherited neuropathies is based on the landmark studies of Dyck and Lambert in 1968 (Table 2). These authors also introduced the term hereditary motor and sensory neuropathy (HMSN), which is used interchangeably with Charcot-Marie-Tooth (CMT*)* ***(Lewis et al., 2010).***

Table (2): Classification of inherited neuropathies:

Type	Features
HMSN type I A and B Dominantly inherited hypertrophic neuropathy	Slow nerve conduction velocities Distal weakness, mild sensory loss Palpable nerves Decreased reflexes
HMSN type II Neuronal type of peroneal muscular atrophy	Normal nerve conduction velocities Distal weakness, mild sensory loss Nonpalpable nerves Autosomal dominant
HMSN type III Hypertrophic neuropathy of infancy (Dejerine and Sottas)	Delayed motor development Severe motor-sensory loss Slow nerve conduction velocities Autosomal recessive
HMSN type IV Hypertrophic neuropathy (Refsum) (Associated with phytanic acid excess)	Refsum disease
HMSN type V (Associated with spastic paraplegia)	Spastic paraplegia present
HMSN type VI (With optic atrophy)	Optic atrophy present
HMSN type VII	Retinitis pigmentosa present

(Lewis et al., 2010)

Table (3): Molecular Genetic Classification of CMT Disease and Related Disorders:

DISORDER	LOCUS	GENE
CMT1		
CMT1A	17p11.2	*PMP-22*
CMT1B	1q22-q23	*PMZ*
CMT1C	16p13.1	*LITAF*
CMT1D	10q21	*EGR2*
CMTX		
CMTX1	Xq13.1	*Cx32*
CMTX2	Xq24	?
CMT2		
CMT2A	1p35	*KIF1Bb*
CMT2B	3q13-q22	?
CMT2C	12q24	?
CMT2D	7p15	?
CMT2E	8p21	*NF-L*
$CMT2P_0$	1q22	*PMZ*
HNPP	17p11.2	*PMP22*
DSS		
	1q22-q23	*PMZ*
	17p11.2	*PMP22*
	10q21-q22	*EGR2*
AR CMT		
CMT4A	8q21	*GDAP1*
CMT4B	11q22	*MTMR2*
CMT4C	5q23-q33	?
CMT4D	8q24	*NDRG1*
CMT4E	10q21-q22	*EGR2*
CMT4F	19q13	*Periaxin*

AR, autosomal recessive; CMTX, X-linked CMT; Cx32, connexin-32; DSS, Dejerin-Sottas syndrome; *EGR2*, early growth response 2 gene; GDAP1, ganglioside-induced differentiation-associated protein 1; HNPP, hereditary neuropathy with liability to pressure palsies; KIF1Bb, microtube motor KIF1Bb; *LITAF* gene, lipopolysaccharide-induced tumor necrosis factor-α factor, MTMR2, myotubularin-related protein 2; NDRG1, N-*myc* downstream regulated gene 1; *NF-L*, neurofilament light chain gene; pm, point mutations; PMP-22, peripheral myelin protein-22; PMZ, myelin protein zero gene***(Jeffrey et al.,2008).***

Muscle Diseases

Introduction:

Muscle weakness may result from lesions of the corticospinal tract or the motor unit. Central disorders are accompanied by the distinctive and recognizable signs of upper motor neuron dysfunction. However, lesions of the motor unit (which includes the anterior horn cell, peripheral motor nerve, and muscle) are all manifested by flaccid weakness, wasting, and depression of tendon reflexes ***(Lewis et al., 2010).***

Myopathies:

Myopathies are a heterogeneous group of conditions affecting muscle usually without involvement of the nervous system and independent of any disorder of the neuromuscular junction. They have a diverse aetiology. The muscular dystrophies are the most common of such disorders and Duchenne muscular dystrophy (DMD) is the most common muscular dystrophy. However the broad range of myopathies is outlined in the boxes below which include some of the rare primary disorders of muscle as well as acquired myopathies.

Most of the congenital myopathies are chronic and slowly progressive. However, metabolic, inflammatory, toxic and endocrine myopathies present subacutely or even acutely and this requires awareness amongst front line physicians to recognise and diagnose myopathy ***(Mellion and Brian, 2009).***

Classification:

Table (4): The primary myopathies ***(Lopate and Glenn, 2009).***

The primary myopathies

- *Muscular dystrophies* - disorders of dystrophin:
  - Duchenne muscular dystrophy (DMD) including Becker muscular dystrophy - DMD is the most common childhood-onset muscular dystrophy
  - Fascioscapulohumeral muscular dystrophy
  - Limb girdle muscular dystrophy
  - Emery-Dreifuss muscular dystrophy
  - Rare forms of muscular dystrophy including:
    - Distal muscular dystrophy
    - Oculopharyngeal muscular dystrophy
    - Congenital muscular dystrophy (CMD) - caused by genetic mutations and generally autosomal recessive disorders:
      - Extracellular matrix protein defects:
        - Laminin-alpha 2 deficiency
        - Ullrich CMD
      - Integrin-alpha7 deficiency
      - Glycosyltransferases:
        - Walker-Warburg syndrome
        - Muscle-eye-brain disease (MEB)
        - Fukuyama CMD - quite common in Japan (7-12 per 100,000)
        - CMD with laminin deficiency (2 types)
        - CMD with mental retardation
      - Proteins of the endoplasmic reticulum:
        - Rigid-spine syndrome
- *Congenital myopathies* - these are rare (unknown incidence) conditions, in which gene defects lead to muscle protein defects:
  - Nemaline rod myopathy
  - Central core disease
  - Centronuclear myopathy
  - Minimulticore myopathy
  - Type 1 fibre predominance ***(Lopate and Glenn, 2007).***
- *Metabolic myopathies*:
  - Hereditary muscle disorders caused by enzymatic defects (usually considered to be inborn errors of metabolism affecting the 3 major pathways of ATP supply) and relatively rare (much less common than the muscular dystrophies):
    - Glycogen storage diseases
      - Pompe disease - Acid maltase deficiency (prevalence 1 in 40,000)
      - McArdle disease - (prevalence 1 in 100,000)
      - Other forms
    - Lipid storage disease
      - Carnitine palmitoyltransferase deficiency - (relative deficiency identified in as many as 1 in 150 patients)
      - Myopathic carnitine deficiency
    - Disorders of purine nucleotide metabolism (affects replenishment of ATP)
    - Mitochondrial disorders

Table (5): The acquired myopathies

The acquired myopathies

- *Secondary metabolic and endocrine myopathies*:
  - Thyroid disease:
    - Myxoedema can present with myopathy
    - Hyperthyroidism
  - Parathyroid dysfunction:
    - Hypoparathyroidism - causes tetany
    - Hyperparathyroidism - causes proximal myopathy
  - Pituitary dysfunction, for example Addison disease (myopathy through either adrenal dysfunction or secondary thyroid dysfunction)
  - Corticosteroids:
    - Cushing's disease
    - Exogenous steroids - especially high doses (over 25 mg per day)
  - Biochemical:
    - Hypokalaemia and hyperkalaemia can cause muscle weakness and myotonia (stiffness)
    - May be caused by varieties of acute periodic paralysis (genetic)
    - Secondary to acute gastrointestinal loss
    - Secondary to endocrine disease
    - Renal disease
    - Excessive liquorice ingestion
  - Diabetes mellitus

- *Dermatomyositis and polymyositis* - these are inflammatory myopathies (possible autoimmune basis) with weakness, endomysial inflammation and elevated muscle enzymes:
  - Primary polymyositis (idiopathic adult)
  - Dermatomyositis (idiopathic adult)
  - Childhood dermatomyositis (or myositis with necrotising vasculitis)
  - Polymyositis associated with connective tissue disorder
  - Polymyositis or dermatomyositis associated with neoplasia
- *Drug induced myopathy*:
  - Statins
  - Steroids
  - Cocaine
  - Colchicine
- *Infectious causes*:
  - Trichinosis
  - Toxoplasmosis
  - HIV
  - Coxsackie viruses
  - Influenza
  - Lyme disease
- *Polymyalgia rheumatica*:
  - Proximal myopathy with associated muscle tenderness

(Katiriji and Tarakad, 2007)

Pathology and Pathogenesis

- Peripheral nerve pathology

Nerve biopsy:

The pathology of PNS is a complex and poorly understood discipline. Because biopsy of peripheral nerves results in a permanent loss of motor or sensory function, most of what is known about peripheral nerve pathology has come from studies involving small numbers of patients (often involving only a single pure-sensory nerve, the sural nerve) and from experimental animal data ***(Midroni and Bilbao, 1995).***

The interpretation of a nerve biopsy requires correlation of histological changes, with clinical information including the results of electrophysiological investigations ***(Hilton et al., 2007).***

Indications for nerve biopsy:

The major indications for nerve biopsy are when vasculitis or amyloidosis are strongly suspected. Additional indications for nerve biopsy include other autoimmune inflammatory conditions (e.g., sarcoidosis), possible infectious processes (e.g., leprosy), and tumor infiltration (e.g., lymphoma and leukemia). Also, a nerve biopsy may be required for diagnosis of a tumor of the peripheral nerve (e.g.,

perineurioma). Less commonly, nerve biopsy may be warranted to diagnose uncommon forms of hereditary neuropathy when DNA testing is not available or is negative (e.g., giant axonal neuropathy and polyglucosan body neuropa***) (Anthony and James, 2008).***

A superficial sensory nerve that is clinically affected and also abnormal on sensory nerve conduction studies usually is biopsied. The most common nerve biopsied is the sural nerve. A superficial peroneal nerve biopsy is particularly useful when vasculitic neuropathy is suspected because the underlying peroneus brevis muscle can also be biopsied through the same incision site, thereby increasing the diagnostic yield ***(Hilton et al., 2007).***

The nerve biopsy is divided into several portions so that, different types of studies can be performed. A small piece at the most proximal end is taken for frozen section. This piece is rapidly frozen in mounting medium for immunofluorescence studies. These studies can reveal the deposition of immunoglobulins or other inflammatory markers such as complement or fibrinogen. Routine paraffin embedding (following fixation in formalin) is performed on a portion of tissue taken from the proximal and distal segments of the nerve biopsy. The paraffin sections can be stained with hematoxylin and eosin, trichrome, Luxol fast blue (stains myelin blue), Bodian stain or neurofilament stains for axons, Congo red, Alcian blue, or cresyl violet for amyloid, and periodic acid –

schiff stain (PAS) when polyglucosan body neuropathy is expected . Immunohistochemistry studies can be done to better assess inflammatory cell infiltrates and other specific stains done to better evaluate Schwann cells and perineurial cells when indicated. The paraffin-embedded tissue is most useful for evaluating signs of vasculitis, other inflammatory cell infiltrates including granulomas and lymphoma, infection (e.g., leprosy), and amyloidosis. In addition, loss of myelinated nerve fibers can be appreciated with various stains of paraffin-embedded tissue ***(Dyck et al., 2005).***

The semithin and electron microscopic (EM) analyses are most important in assessing the axons, Schwann cells, and myelin sheath of myelinated nerve fibers as well as in looking at abnormalities in small unmyelinated nerve Fibers ***(Anthony and James, 2008).***

Structure of Normal Nerve:

Peripheral nerves consist of myelinated and unmyelinated nerve fibers or axons organized into fascicles (Fig. 1)**.** Each fascicle is surrounded by the perineurium, which is composed of concentric layers of specialized cells separated by intervening layers of longitudinally oriented collagen. Several fascicles are bound together by fibroadipose tissue containing arteries, veins, and lymphatics, termed *epineurium*. The *endoneurium* represents the interstitial connective tissue and cellular elements of a given nerve fascicle. Within a given

fascicle is a population of nerve fibers, which are composed of individual axons surrounded by a myelin sheath (Fig. 2). The junction between two adjacent Schwann cells in a myelinated axon viewed longitudinally is termed a *node of Ranvier* and accounts for the saltatory conduction of the nerve impulse ***(Anthony and James, 2008).***

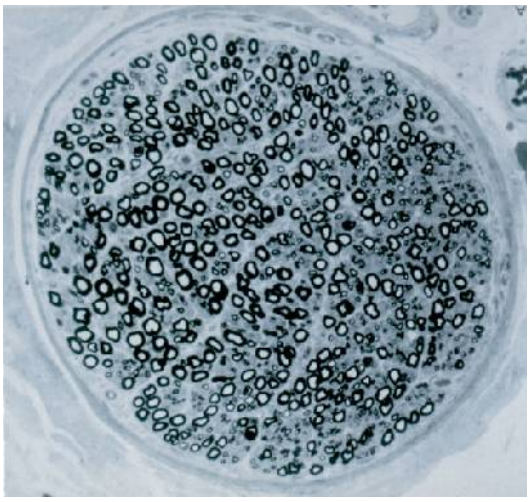

Fig. (1): Semithin section reveals a normal nerve fascicle ***(Younger et al., 1999).***



Fig. (2): Individual myelinated fibers that populate a fascicle of nerve in semithin sections are recognized by their large size compared with small unmyelinated fibers seen at the bottom of the fascicle ***(Younger et al., 1999).***

Under normal circumstances, perineurial and endoneurial tight junctions protect the peripheral nerves from systemic illness. Peripheral nerves react to infection, vascular inflammation, medication toxicity, vitamin deficiency, endocrinopathy, genetic influences, mechanical injury, and many nonspecific injurious processes in a limited number of ways, mainly with disruption of the blood-nerve barrier and increased vascular permeability. This reaction allows the entry of vasoactive substances, complement activation, and inflammatory intermediates, including cytokines, interleukins, and tumor necrosis factor secretion; edema; inflammation; ischemia; and eventually infarction of nerve fibers ***(Anthony and James, 2008).***

Nerve biopsy has proved to be particularly informative when techniques such as single teased fiber preparations, semithin sections, ultrastructural studies, and morphometry are applied to quantitate the nerve fiber pathology ***(Walter et al., 2004).***

Conventional hematoxylin and eosin sections of nerve may reveal a loss of large myelinated axons indicating neuropathy ***(Anthony and James, 2008).***

Peripheral Neuropathy:

- **General considerations**

In the evaluation of peripheral nerve biopsy specimens for neuropathy, the pathologist's task may be considered as one of examination of three “compartments”: axons, myelin sheaths, and the supporting connective tissues and vascular structures. Using this method, the pathologist may classify pathologic alterations as axonal neuropathy, demyelinating neuropathy, inflammatory neuropathy, or as a process of the supporting and/or vascular tissues, such as vasculitis, storage disease, and infectious or neoplastic infiltration. In most specimens, the histologic features are not specific to a certain disease entity and must be correlated with clinical, electrophysiologic, and, occasionally, imaging data to arrive at a correct diagnosis ***(Midroni and Bilbao, 1995).***

Axonal degeneration:

Primary damage to the axon may either be due to a discrete, localized event (trauma, ischemia, etc.) or be due to an underlying abnormality of the neuronal cell body or ganglion (neuronopathy) or its axon (axonopathy). These processes lead to axonal degeneration with secondary disintegration of its myelin sheath (Fig. 3A). If a nerve is transected, the distal portion of the nerve undergoes an acute disintegration (termed Wallerian degeneration) characterized by breakdown of the

axon and its myelin sheath into fragments forming small oval compartments (i.e., myelin ovoids). These breakdown products undergo phagocytosis by macrophages and Schwann cells. The proximal stumps of axons that have degenerated sprouts of new axons may attempt to grow along the course of the degenerated axon. Small clusters of these regenerated axons, which are small in diameter and thinly myelinated, can be recognized on cross section of semithin and EM sections (Fig. 3B) ***(Anthony and James, 2008).***

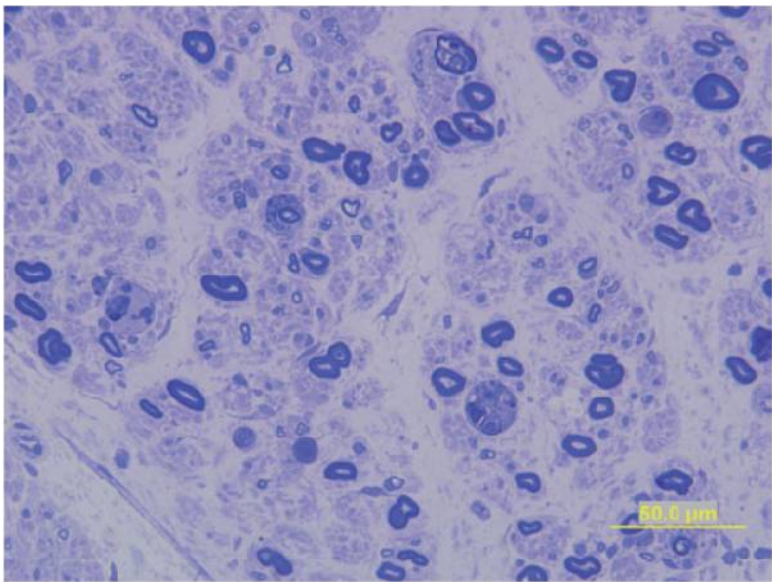

(A)

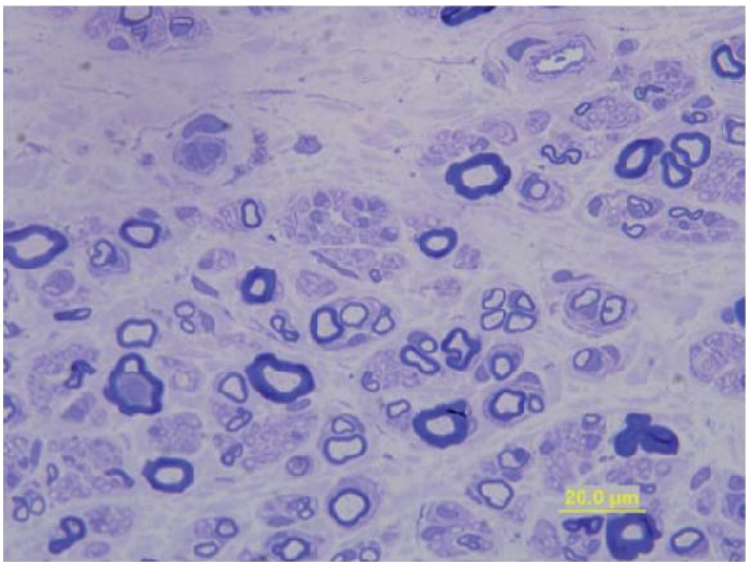

(B)

Fig. (3): A semithin section reveals several fibers undergoing active axonal degeneration (Wallerian degeneration) is apparent **(A).** As nerve fibers attempt to regenerate these send out nerve sprouts. These can be appreciated and groups of thinly myelinated nerve fibers surrounded by the same basement membrane **(B)** ***(Anthony and James, 2008)***.

Predominantly axonal disorders:

- Diabetic neuropathy,
- Alcoholic neuropathy,
- Medication-related neuropathy (e.g., metronidazole, colchicine, nitrofurantoin, isoniazid).
- Systemic disease–related neuropathy (e.g., chronic renal failure, inflammatory bowel disease, connective tissue disease)
- Thyroid neuropathy
- Heavy metal toxic neuropathy (lead, arsenic, cadmium)
- Porphyric neuropathy
- Paraneoplastic neuropathy
- Syphilitic, Lyme neuropathy
- Sarcoid neuropathy
- Human immunodeficiency virus–related neuropathy
- Hereditary neuropathies (Charcot-Marie-Tooth, type 2; familial amyloid; mitochondrial)
- Critical illness neuropathy

(Venu et al., 2008).

Demylinating neuropathies:

Segmental demyelination and remyelination are observed best on semithin sections of nerve embedded in plastic and stained with toluidine blue, in teased fiber preparations, and on electron microscopy. Demyelination and remyelination occur in response to diverse inflammatory and immunologic conditions

leading to loss of myelin from one or more internodes along the myelinated axon, reflective of Schwann cell damage followed by proliferation of Schwann cells with the formation of regenerative clusters of nerves, shorter internodes on teased fiber analysis, thinly myelinated fibers, and onion bulbs (Fig. 4) ***(Lacomis, 2005).***

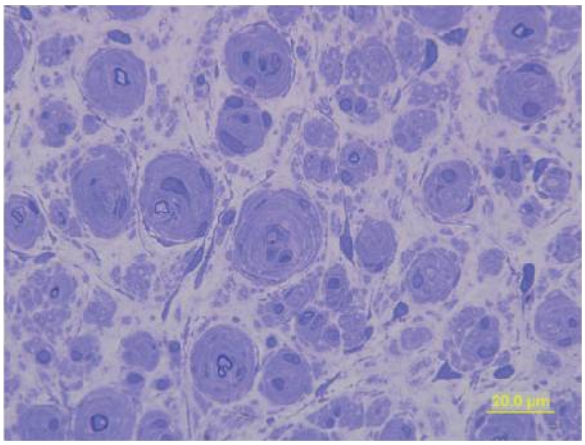

Fig. (4): Onion bulb formation. With recurrent bouts of demyelination and remyelination, concentric layers of Schwann cell processes accumulate around the axons forming onion bulbs ***(Lacomis, 2005).***

Important diseases with onion bulbs:

- Charcot-Marie-Tooth disease
- Dejerine-Sottas disease (HSMN-3)
- Hereditary neuropathy with pressure palsies (HNPP)
- CIDP
- Refsum's disease (HMSN-4)
- Congenital dysmyelinating neuropathies
- Metachromatic leucodystrophy (MLD)
- Globoid cell (Krabbe's) leucodystrophy
- Adrenoleucodystrophy
- IgM paraprotein neuropathy

(Midroni and Bilbao, 1995)

Teased fiber preparation, with this method, individual myelinated fibers are separated from the nerve fascicles and lightly stained, allowing examination of the integrity and thickness of the myelin sheath as well as revealing alterations in internode length. Thus, one can better quantify the degree of demyelinated or thinly myelinated axon, axons with increased or redundant myelin, and axons undergoing active Wallerian degeneration. (Fig. 5) ***(De Girolami et al., 2003).***

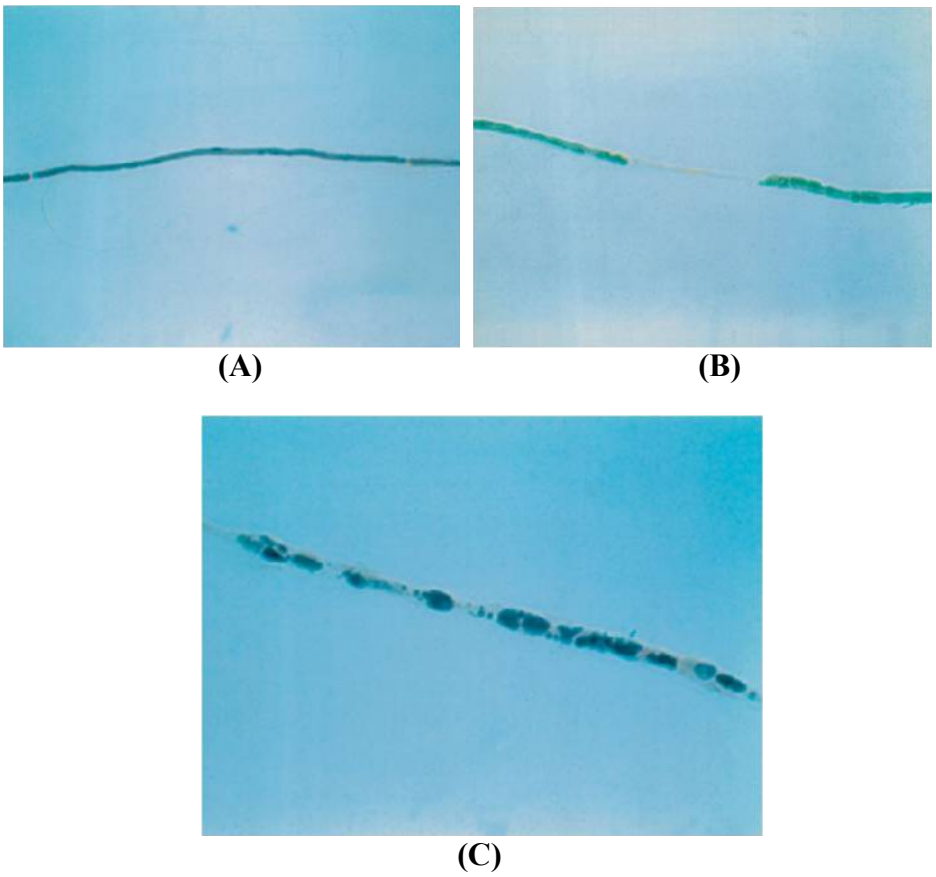

(A) **(B)**

(C)

Fig. (5): Teased nerve fibers. **(A)** A normal teased fiber internode is seen **(B)** as well as a short, demyelinated internode**. (C)** A teased nerve fiber segment undergoing Wallerian degeneration with myelin ovoids is appreciated in ***(De Girolami et al., 2003).***

Demyelinating Neuropathies

- Charcot-Marie-Tooth disease
- HNPP
- Inflammatory neuropathies (GBS and CIDP)
- Monoclonal gammopathies and paraproteinemias
- Multifocal motor neuropathy with conduction block
- Neuropathies caused by drugs such as amiodarone and suramin
- Neuropathies caused by infections (diphtheria) or toxins (arsenic)

(Charles et al., 2010)

GBS:

GBS is characterized by acute onset of peripheral and cranial nerve dysfunction. Viral respiratory or gastrointestinal infection, immunization, or surgery often precedes neurologic symptoms by 5 days to 4 weeks. Symptoms and signs include rapidly progressive symmetric weakness, loss of tendon reflexes, facial diplegia, oropharyngeal and respiratory paresis, and impaired sensation in the hands and feet. The condition worsens for several days to 3 weeks, followed by a period of stability and then gradual improvement to normal or nearly normal function. Early plasmapheresis or intravenous immunoglobulin (IVIG) accelerates recovery and diminishes the incidence of long-term neurologic disability. In North America and Europe, acute inflammatory demyelinating

polyneuropathy (AIDP) accounts for over 90% of GBS. GBS also includes acute motor axonal neuropathy (AMAN), acute motor and sensory axonal neuropathy (AMSAN), Miller Fisher syndrome (MFS), and acute autonomic and sensory neuropathies ***(Lewis et al., 2010)***.

Pathology:

The peripheral nerves in acute GBS often show inflammatory cell infiltrate, with associated areas of demyelination. This inflammatory infiltrate is mainly perivascular and comprised of lymphocytes and macrophages. Electron microscopy shows that macrophages cause the myelin damage, and penetrate the basement membrane around nerve fibres before stripping myelin sheaths off axons. Spinal nerve roots may be particularly affected, but changes are found at all levels of the peripheral nervous system. Teased peripheral sensory nerve fibre preparations may show marked segmental demyelination. Some Wallerian degeneration may occur. Biopsy of the sural nerve may show surprisingly few abnormalities in comparison to the marked clinical severity of the neuropathy; this may reflect the distal and purely sensory nature of the sural nerve. Sensory nerve biopsy is generally unhelpful in establishing the diagnosis of GBS; more typical demyelinative changes being present in motor nerves, which are not amenable to routine biopsy ***(Michael et al., 2001).***

CIDP:

CIDP is a chronic acquired demyelinating sensorimotor neuropathy that may be monophasic, relapsing, or progressive. By definition, CIDP develops over at least a 2-month period versus acute inflammatory demyelinating polyneuropathy, which it otherwise resembles. CIDP occurs in all age groups with a mean age range of 30 to 50 years. Women are slightly more likely to be affected than men. Weakness and sensory loss begin insidiously and progress over a period of months to years. Weakness is commonly proximal as well as distal. Patients can become bedridden. Loss of proprioception from damage to large-diameter sensory nerves may affect balance and result in an action tremor. Deep tendon reflexes are usually absent or markedly decreased. Facial weakness (15%), ptosis or ophthalmoparesis (5%), and papilledema occur occasionally. Variant forms include pure motor, pure sensory and multifocal disease ***(Jeffrey et al., 2008).***

Pathology:

Nerve biopsies may reveal segmental demyelination and Remyelination. Chronic demyelination and remyelination result in proliferation of surrounding Schwann cell processes forming the so-called "onion bulbs". Schwann cell proliferation can lead to a hypertrophic appearance of the nerve. Inflammatory cell infiltrate may be evident in the epineurium, perineurium, or

endoneurium and was usually perivascular ***(Anthony and James, 2008).***

Inherited Neuropathies:

Despite phenotypic variability, the typical clinical course of CMT1 and CMT2 patients includes normal development before weakness, and sensory loss appearing gradually within the first 2 decades of life. Affected children are often slow runners and have difficulty with activities that require balance .Most patients remain ambulatory throughout life and have a normal lifespan. A minority of CMT patients have a more severe phenotype with delayed motor milestones and onset in infancy, termed *Dejerine-Sottas neuropathy.* Patients with hereditary motor neuropathies sometimes have mild sensory abnormalities, and patients with hereditary sensory and autonomic neuropathies usually have some weakness ***(Nezam et al., 2007).***

Pathology:

Segmental demyelination, remyelination, and axonal loss are characteristic features of the various demyelinating forms of CMT1. In Dejerine-Sottas neuropathy, the demyelination is more severe. In CMT1, onion bulbs of concentric Schwann cell lamellae are usually present on nerve biopsies, with loss of both small- and-large diameter myelinated fibers and sometimes axons. Focal, sausage-like thickenings of the myelin sheath (tomacula) are characteristic of hereditary neuropathy with

liability to pressure palsies but may also be found in other forms of CMT1, particularly CMT1B ***(Nezam et al.,2007).***

Infectious neuropathies:

Infectious neuropathies constitute a leading cause of neuropathies worldwide. Although relatively uncommon in developed countries, neuropathy caused by leprosy is the most frequent cause of PNS disorders from an infective agent, and also one of the few curable peripheral neuropathies. Peripheral neuropathies associated with HIV infection are found in up to 50% of patients ***(Said, 1994)***. Rare infectious causes of neuropathy, such as poliomyelitis and diphtheria, and other treatable neuropathies, such as Lyme disease, should not be forgotten. The following sections briefly cover leprous and HIV-related neuropathies ***(Manji, 2000)***.

Leprous neuropathy:

Pathology:

The histopathological and clinical picture varies widely in different individuals. This reflects different degrees of cell-mediated immunity ***(Michael et al., 2001).***

Tuberculous Leprosy:	Mid-Borderline Leprosy:	Lepromatous Leprosy:
Localized granulomas and giant cells encompassed by dense lymphocytic infiltrate extending to epidermis. Fite stain: negative for bacteria.	Granulomas with epithelioid cells but no giant cells. Scant lymphocytes, but if present diffuse along with organism-laden foamy macrophages Not localized by zones of lymphocytes. Lymphocytes, if present, are diffusely infiltrating Fite stain: slightly positive.	Scant lymphocytes, but if present diffuse along with organism-laden foamy macrophages. Fite stain: marked positive

HIV-related Neuropathies:

Several neuropathies affect patients infected with HIV, depending on the stage of the illness and the immunocompetence of the patient. An acute demyelinating neuropathy indistinguishable from sporadic GBS may occur early in the course of infection, Subacute demyelinating neuropathy, clinically indistinguishable from idiopathic CIDP, is usually found in HIV-positive patients before there is evidence of immunodeficiency (AIDS). In patients who fulfill diagnostic criteria for AIDS, there is frequently a distal

sensorimotor polyneuropathy with axonal features ***(*Lewis *et al., 2010).***

Nerve compression:

The pathologic features of nerve compression have been described in animal studies**.** The principal finding is an axonal neuropathy, characterized by degenerating axons and regeneration. Large myelinated axons at the periphery of the nerve are most affected. This relative sparing of the fibers in the central portion of the nerve has led some investigators to conclude that the mechanism of injury is shear forces; if ischemia were the mechanism, it is expected that the central fibers would be preferentially affected ***(Midroni and Bilbao, 1995).***

Toxic neuropathies:

Peripheral neuropathy is a common manifestation of toxic exposure to metals, an increasing number of industrial and environmental chemicals, and therapeutic agents. Most of these agents cause axonal degeneration, although some, notably lead and amiodarone, primarily attack myelin ***(McLeod, 1995).***

Paraneoplastic neuropathy:

Nerve biopsy may reveal infiltration by tumor cells, axonal degeneration, or demyelination. A primarily motor syndrome of subacute onset rarely occurs in Hodgkin disease and other lymphomas. In these patients, the predominant lesion is degeneration of anterior horn cells, but demyelination,

perivascular mononuclear cell infiltrates, and alterations in Schwann cell morphology in ventral roots are also observed ***(*Lewis *et al., 2010)***

Paraneoplastic sensorimotor polyneuropathy:

Nerve biopsies reveal a general reduction in all myelinated fibers often with perivascular inflammation. Necrotizing vasculitis is extremely rare ***(Amato and Dumitru, 2002).***

Neuropathy secondary to tumor infiltration:

Malignant, in particular leukemic and lymphomatous, cells can occasionally infiltrate peripheral nerves, leading to mononeuropathy, mononeuropathy multiplex, polyradiculopathy, plexopathy, or even a generalized symmetric distal or proximal and distal polyneuropathy ***(Grisold et al., 2000).***

Pathogenesis of peripheral neuropathy:

GBS:

The bulk of experimental and clinical evidence suggests that GBS is an organ-specific, immune-mediated disorder caused by a synergistic interaction of cell-mediated and humoral immune responses to still incompletely characterized peripheral nerve antigens ***(Kieseier et al., 2006).***

A preceding infection may trigger an autoimmune response through “molecular mimicry” in which the host

generates an immune response against an infectious organism that shares epitopes with the host's peripheral nerves. At the onset of disease, activated T cells play a major role in opening the blood-nerve barrier to allow circulating antibodies to gain access to peripheral nerve antigens. T-cell activation markers (interleukin-6, interleukin-2, soluble interleukin-2 receptor, and interferon-γ) and TNF-α, a proinflammatory cytokine released by T cells and macrophages, particularly IL-23 ***(Hu et al., 2006)***, are increased in patient serum. In addition, adhesion molecules and matrix metalloproteinases are critically involved in facilitating recruitment and transmigration of activated T cells and monocytes through the blood-nerve barrier. Soluble E-selectin, an adhesion molecule produced by endothelial cells, and metal-loproteinases are increased in patients with GBS during the early stages of disease. A cell-mediated immune reaction against myelin components is supported by experimental allergic neuritis, the accepted animal model for Acute inflammatory demyelinating polyradiculoneuropathy (AIDP). Experimental allergic neuritis can be produced by active immunization with whole peripheral nerve homogenate, myelin, or PNS-specific myelin basic protein P_2, P_0, or galactocerebroside ***(Jeffrey et al., 2008).***

Several observations indicate that humoral factors also participate in the autoimmune attack on peripheral nerve myelin, axons, and nerve terminals: (1) immunoglobulins and complement can be demonstrated on myelinated fibers of

affected patients by immunostaining; (2) MFS and AMAN are strongly associated with specific antiganglioside antibodies; (3) serum from MFS and AMAN patients contains IgG antibodies that block neuromuscular transmission in a mouse nerve-muscle preparation; (4) complement C1-fixing antiperipheral nerve myelin antibody can be detected in the serum of patients during the acute phase of GBS; (5) intraneural injection of GBS serum into rat sciatic nerve results in secondary T-cell infiltration of the injection site at the time of the appearance of the hind limb weakness, and (6) plasmapheresis or immunoglobulin infusions result in clinical improvement ***(Jeffrey et al.,2008).***

CIDP:

CIDP is an autoimmune disorder, but the antigen(s) to which the immune attack is targeted and specific roles of the humoral and cellular system played in the pathogenesis of CIDP are not known (Fig. 6). Failure of regulatory T-cell mechanism is thought to underlie persistent or recurrent disease, differentiating CIDP from the acute inflammatory demyelinating polyneuropathy form of GBS. The sometimes rapid improvement following plasma exchange or IVIG and the demonstration of immunoglobulin and complement on peripheral nerve tissues suggest a role of the humoral arm of the immune system. Perhaps, some antibodies are directed against neuronal elements (e.g., ion channels), resulting in conduction block and subsequent demyelination ***(Anthony and James, 2008).***

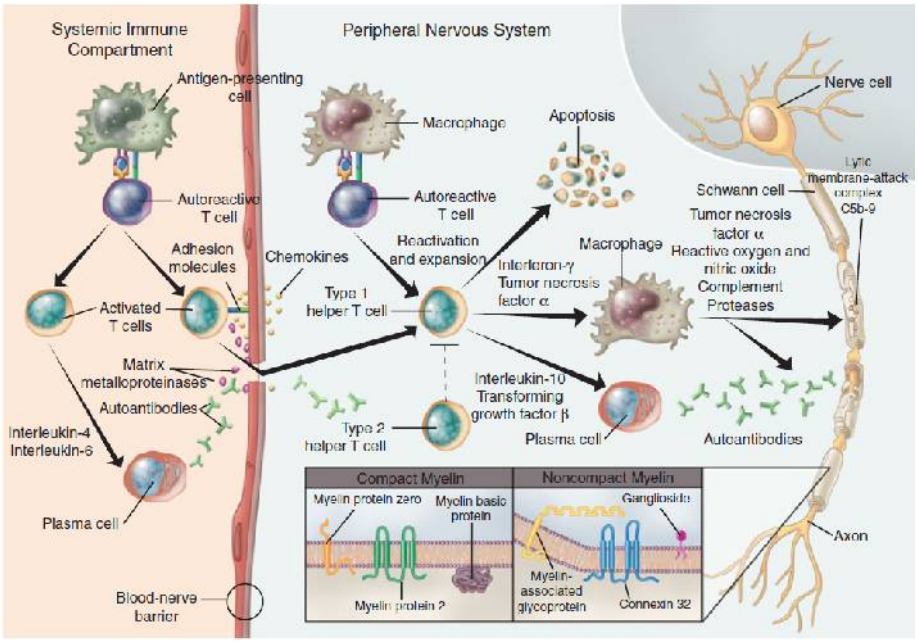

Figure (6): Immunopathogenesis of chronic inflammatory demyelinating neuropathy. A schematic illustration of the basic principles of the cellular and humoral immune responses shows that autoreactive T cells recognize a specific autoantigen in the context of major histocompatibility complex class II and costimulatory molecules on the surface of antigen-presenting cells (macrophages) in the systemic immune compartment. An infection might trigger this event through molecular mimicry, a cross-reaction toward epitopes shared between the microbial agent and nerve antigens. These activated T lymphocytes can cross the blood–nerve barrier in a process involving cellular adhesion molecules, matrix metalloproteinases, and chemokines. Within the peripheral nervous system, T cells activate macrophages that enhance phagocytic activity, the production of cytokines, and the release of toxic mediators, including nitric oxide, reactive oxygen intermediates, matrix metalloproteinases, and proinflammatory cytokines including tumor necrosis factor (alpha) and interferon-(gamma). Autoantibodies crossing the blood–nerve barrier or locally produced by plasma cells contribute to demyelination and axonal damage. Autoantibodies can mediate demyelination by antibody-dependent cellular cytotoxicity, potentially block epitopes that are functionally relevant for nerve conduction, and activate the complement system by the classic pathway, yielding proinflammatory mediators and the lytic membrane-attack complex C5b-9. Termination of the inflammatory response occurs through the induction of T-cell apoptosis and the release of anti-inflammatory cytokines, including interleukin-10 and transforming growth factor (beta). The myelin sheath (inset) is composed of various proteins, such as myelin protein zero, which account for more than 50% of the total membrane protein in human peripheral nervous system myelin, myelin protein 2, myelin basic protein, myelin-associated glycoprotein, connexin 32, and gangliosides and related glycolipids. These molecules have been identified as target antigens for antibody responses with varying frequencies in patients with this disease ***(Koller et al., 2005).***

HMSNs:

From recently published molecular genetic data, CMT disease is now recognized as a heterogeneous disorder, linked to at least eight different genes that encode proteins with diverse functions ***(Warner e al., 1999).***

Mutations in three genes coding for the myelin proteins peripheral myelin protein 22, myelin protein 0, and connexin 32, and in one gene coding for the transcription factor early-growth response 2 element are associated with CMT types 1 and 2, HNPP, Dejerine-Sottas syndrome, and congenital hypomyelination ***(Nelis et al., 1999).***

Other studies have demonstrated that apparent loss-of-function mutations in the periaxin gene cause autosomal recessive Dejerine-Sottas neuropathy or severe demyelinating CMT ***(Takashima et al., 2002).***

Pathology of muscle diseases

Muscle biopsy

Muscle biopsy is the most important and specific diagnostic study of most neuromuscular disorders, if the definitive diagnosis of a hereditary disease is not provided by molecular genetic testing in blood. Not only are neurogenic and myopathic processes distinguished, but also the type of myopathy and specific enzymatic deficiencies may be determined ***(Engel, 2004).***

Indications for muscle biopsy:

A muscle biopsy may be helpful when the patient has objective muscle weakness, abnormal muscle enzymes [e.g., elevated serum creatine kinase (CK) levels], abnormal skeletal muscle MRI, or myopathic electromyographic findings (EMG). These findings may point to a myopathy but not the exact etiology, and therefore a muscle biopsy may be indicated ***(Anthony and James, 2008).***

Preferably, one should biopsy a mildly weak muscle. If the muscle is too weak the tissue typically has end-stage damage. It is often impossible to discern a myopathic process from severe neurogenic atrophy under these conditions. The easiest muscle to biopsy with open surgery is the biceps brachii and is our first choice if clinically affected. Other muscles that are commonly biopsied are the deltoid, triceps, and quadriceps ***(Banker and Engel, 2004).***

Muscle Biopsy Stains:

Table (6): Muscle biopsy stains

Category	Method	Utility
Morphology	Hematoxylin and eosin	Muscle fiber pathology; Nuclei
	Verhof van Giesson (VvG)	Connective tissue; Vessel structure Intramuscular nerve
	Gomori trichrome	Connective tissue; Nemaline rods
Fiber Type Enzymes	Myofibrillar ATPase	Muscle fiber type grouping or Atrophy
	ATPase pH 9.4	Myosin loss; Type 1 or 2 fiber atrophy
	ATPase pH 4.6	Type 2B muscle fibers
	ATPase pH 4.3	Type 2C (Immature) muscle fibers
Oxidative Enzymes	NADH-TR	Muscle fiber internal architecture; Tubular aggregates; Cores
	Succinate dehydrogenase	Mitochondrial pathology Nuclear DNA encoded protein
	Cytochrome oxidase	Mitochondrial pathology Mitochondrial DNA encoded protein
Glycolytic Enzymes	Phosphorylase	Phosphorylase deficiency
	Phosphofructokinase (PFK)	PFK deficiency
Hydrolytic Enzymes	Acid phosphatase	Macrophages; Lysosomes; Lipofuscin
	Non-specific esterase	Macrophages; Lysosomes; Neuromuscular & myotendinous junctions Denervated (small angular) muscle fibers
	Acetylcholinesterase	Neuromuscular & Myotendinous junctions
	Alkaline phosphatase	Regenerating muscle fibers; Immune disease of connective tissue
Storage material	PAS	Glycogen & Carbohydrate disorders
	Alcian blue	Mucopolysaccharide
	Sudan black B	Lipid storage
	Oil red O	Lipid storage
Other	Congo red	Amyloid; Inflammation; Vacuoles
	Myoadenylate deaminase	AMPDA deficiency
	Methyl green pyronine	RNA
	Acridine orange	RNA
	Von Kossa	Calcium
	Alizarin red	Calcium

(Yo Okizuka et al., 2008)

Histochemical studies of frozen sections of the muscle are obligatory in all pediatric muscle biopsies because many congenital and metabolic myopathies cannot be diagnosed from paraffin sections using conventional histologic stains ***(Engel, 2004).***

Muscle histology:

A transverse section of normal muscle shows fibers that are roughly of equal size and average approximately 60 mm transverse diameter (Fig. 7). The muscle fibers of infants and young children are proportionately smaller. Each fiber consists of hundreds of myofibrils separated by an intermyofibrillar network containing aqueous sarcoplasm, mitochondria, and the sarcoplasmic reticulum with the associated transverse tubular system. Surrounding each muscle fiber is a thin layer of connective tissue (the *endomysium*). Strands of connective tissue group fibers into a fascicle, separated from each other by the *perimysium*. Groups of fascicles are collected into muscle bellies surrounded by epimysium. Situated at the periphery of the fibers are the sarcolemmal nuclei ***(Jeffrey et al., 2008).***



Fig. (7): Normal muscle biopsy. The fibers are roughly equal in size, the nuclei are peripherally situated, and the fibers are tightly apposed to each other with no fibrous tissue separating them (Verhoeff-Van Gieson stain) ***(Jeffrey et al., 2008)***

Individual muscle fibers can be classified into four different fiber types based on their staining characteristics and physiologic properties: types 1 (slow twitch, fatigue resistant, and oxidative metabolism), 2A (fast twitch, intermediate fatigue resistance, and oxidative and glycolytic metabolism), 2B (fast twitch, poor fatigue resistance, and glycolytic metabolism), and 2C (undifferentiated and embryonic). In adults, only about

1–2% of muscle fibers are the undifferentiated type 2C fibers. The different muscle fiber types are normally distributed randomly, forming a so-called checkerboard pattern (Fig.8) ***(Anthony and James, 2008).***

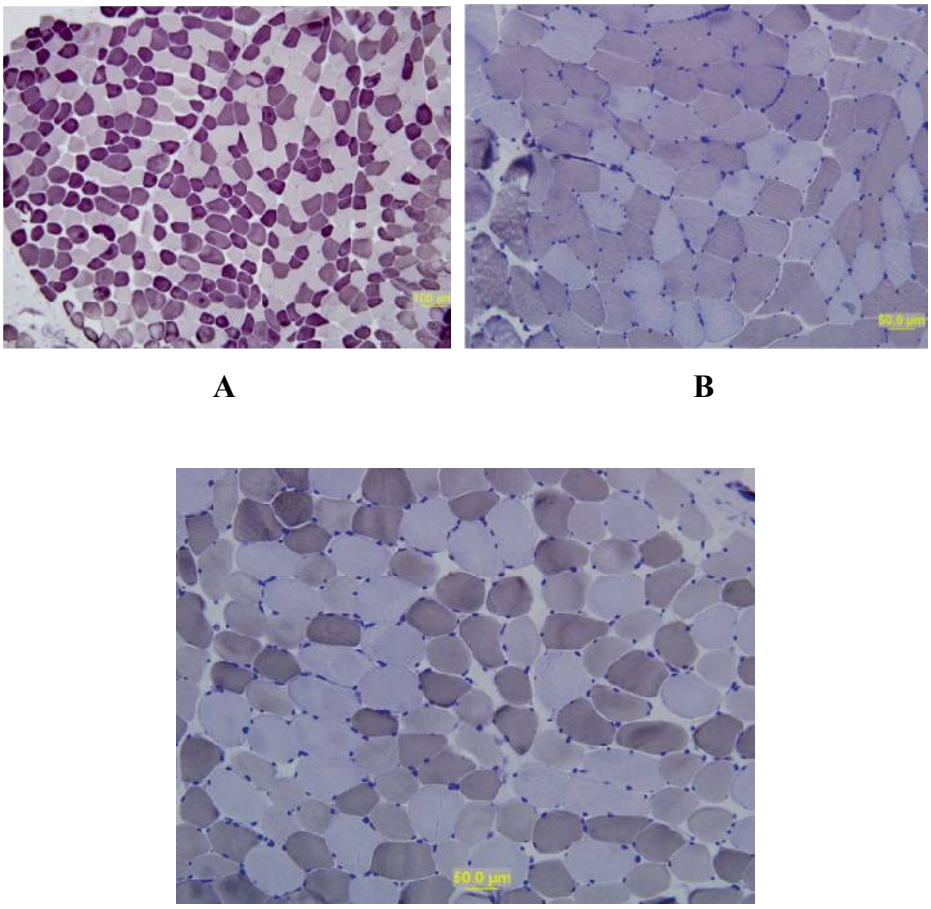

Fig. (8): The myofibrillar adenosine triphosphatase (ATPase) is typically performed at three pHs: 4.3, 4.6, and 9.4. **(A)** Type 1 fibers are lightly stained while type 2 fibers are dark on ATPase 9.4 stain. **(B)** Type 1 fibers are dark while type 2 fibers are light on ATPase 4.3 stain. **(C)** The ATPase 4.6 stains type 1 fibers dark, type 2A fibers light, and type 2B fibers in between ***(Anthony and James, 2008).***

Reactions to Injury:

Muscle abnormalities may be classified on histopathologic and etiologic grounds into three major categories: (1) neurogenic atrophy: a pattern of muscle pathology consequent to denervation and reinnervation; (2) myopathies: inherited and acquired diseases characterized by abnormalities in the muscle fiber itself; these include dystrophies, congenital, inflammatory, metabolic, and toxic myopathies; and (3) disorders of the neuromuscular junction. Patients with neuromuscular junction defects usually have only slight and nonspecific alterations apparent on routine light microscopy and are rarely biopsied except at very specialized centers ***(Anthony and James, 2008).***

(1) Changes of Denervation:

When the muscle loses its nerve supply, the muscle fibers atrophy, often resulting in fiber squeezing into the spaces between normal fibers and assuming an angulated appearance (Fig. 9). Scattered angulated fibers appear early in denervation. Sometimes, picturesque changes in the intermyofibrillar network occur, as in the target fiber, which characterizes denervation and reinnervation This is a three-zone fiber, on which the intermediate zone stains more darkly and the central "bull's eye" stains much lighter than normal tissue (Fig. 10). Often, a neighboring nerve twig reinnervates a denervated fiber. This results in the same anterior horn cell supplying two or

more contiguous fibers. If that nerve twig then undergoes degeneration, instead of only one small, angulated fiber produced, a small group of atrophic fibers develops. Group atrophy suggests denervation (Fig. 11). As the process continues, large groups of geographical atrophy occur, in which entire fascicles are atrophic. In addition to the change in size, a redistribution of the fiber types occurs as well. Normally, a random distribution of type 1 and 2 muscle fiber types exists, sometimes incorrectly called a *checkerboard* or *mosaic pattern*. The same process of denervation and reinnervation results in larger and larger groups of contiguous fibers supplied by the same nerve. Because all fibers supplied by the same nerve are of the same fiber type, groups of type 1 fibers next to groups of type 2 fibers replace the normal random pattern. This fiber type grouping is pathognomonic of reinnervation (Fig. 12). When long-standing denervation is present, the atrophic muscle fibers almost disappear, leaving small clumps of pyknotic nuclei in their place ***(Greenberg et al., 2006).***

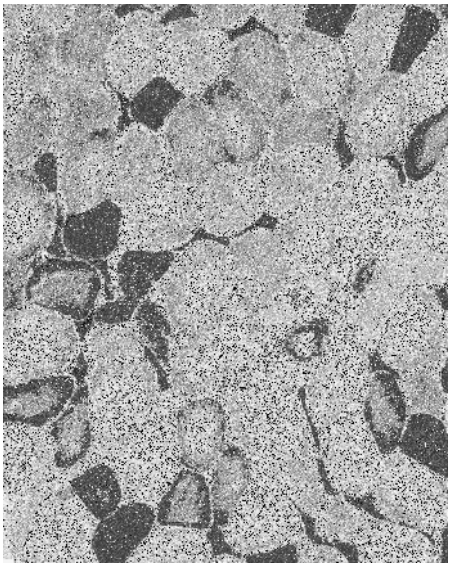

Fig. (9): Denervation. Notice the small, dark, angulated fibers demonstrated with this oxidative enzyme reaction (nicotinamide adenine dinucleotide dehydrogenase stain).

Fig. (10): Denervation. Target fibers (nicotinamide adenine dinucleotide dehydrogenase stain).

Fig. (11): Denervation. Small groups of atrophic fibers are scattered throughout the biopsy (modified Gomori-trichrome stain)

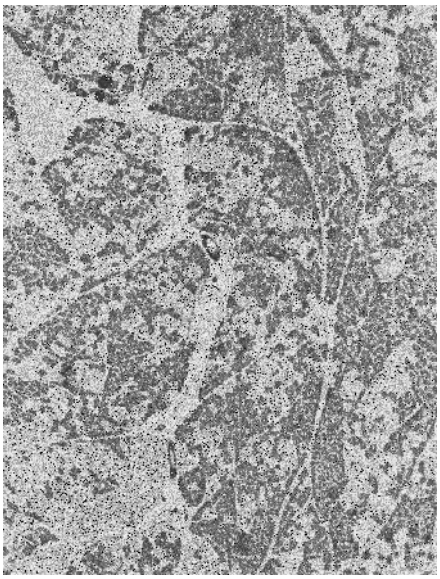

Fig. (12): Chronic denervation and reinnervation. (myosin adenosine triphosphatase stain, pH 9.4)

(2) Myopathic Changes:

Primary diseases of the muscle cause much greater variation in pathological changes than does denervation. The type of change occurring depends on the type of muscle disease. The normal peripherally placed nuclei may migrate toward the center of the fiber. Occasional central nuclei may be seen in normal muscle (up to 2% of fibers), but when they are numerous, they usually indicate a myopathic, often dystrophic, disease. Numerous internal nuclei are a feature of the myotonic dystrophies and the limb-girdle muscular dystrophies (LGMDs). Occasionally, one sees internal nuclei in some of the chronic denervating conditions (e.g., juvenile spinal muscular atrophy). Necrosis of muscle fibers, in which the fiber appears liquefied and later presents as a focus of phagocytosis, occurs in many of the myopathies. These changes usually represent an active degenerative process. They often are a feature of myoglobinuria, toxic myopathies, inflammatory myopathies, and metabolic myopathies, and are also seen in dystrophies. Fiber-size variation may occur in primary diseases of muscle, with large fibers and small fibers intermingling in a random pattern (Fig. 13).

It is sometimes the only indication of the pathological process. Fiber splitting often accompanies muscle fiber hypertrophy. In transverse section, recognition of split fibers is by a thin fibrous septum, often associated with a nucleus that crosses partway, but not all the way, across the fiber. A detailed

study of serial transverse section may reveal more split fibers than in a single section. Fiber splitting is particularly visible in dystrophic conditions, such as LGMD, but not usually a feature of Duchenne muscular dystrophy (DMD), Becker muscular dystrophy (BMD), or acquired myopathies, such as polymyositis) ***(Jeffrey et al., 2008).***

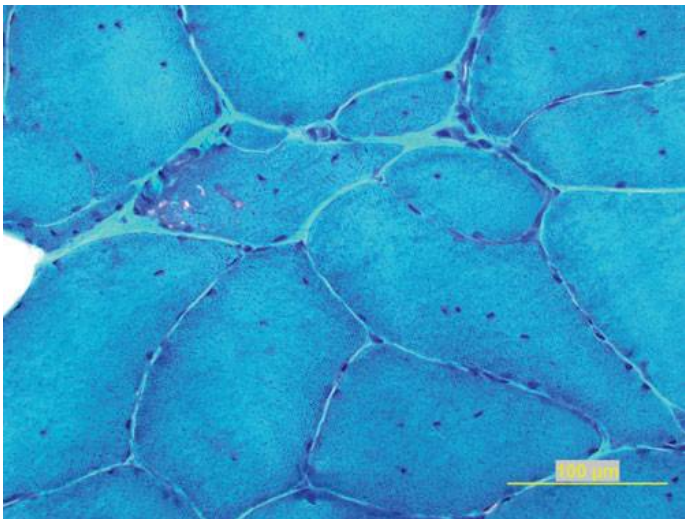

Fig. (13): Variability in muscle fiber size, increased internalized nuclei, muscle fiber splitting, and small intracytoplasmic vacuoles are nonspecific myopathy features appreciated on this modified Gomori-trichrome stain ***(Jeffrey et al., 2008).***

Degeneration and regeneration of fibers characterize many illnesses. When this occurs, the regenerating fibers often become basophilic and myonuclei enlarge because of the accumulation of RNA needed for protein synthesis. Fiber basophilia is a sign of an active myopathy. It is particularly characteristic of DMD, in which small basophilic groups of fibers may be prominent. Cellular responses include frank inflammatory reactions around blood vessels, which

characterize the collagen vascular diseases and dermatomyositis. Endomysial inflammation with invasion of non-necrotic muscle fibers occurs in inclusion body myositis and polymyositis. Importantly, pronounced inflammatory cellular responses may occur in dystrophies, particularly facioscapulohumeral muscular dystrophy (FSHD) and dysferlinopathies. Even the so-called congenital inflammatory myopathies actually represent forms of congenital muscular dystrophy ***(Hackman et al., 2002).***

Fibrosis is another reactive change in muscle. Normally, a very thin layer of connective tissue separates the muscle fibers. In dystrophic conditions, this layer thickens, and muscle fibrosis may be quite pronounced. In DMD, muscle fibrosis gives the muscle a hard, gritty texture; this texture also occurs in some congenital dystrophies. In the inflammatory myopathies, there may be a loose edematous separation of fibers, but fibrosis is not usually characteristic of the active phase of the disease, except where associated with systemic sclerosis ***(Jeffrey et al., 2008).***

Changes in the intermyofibrillar network pattern are common in myopathic disorders. There is often a moth-eaten, whorled change to the intermyofibrillar network in LGMD and FSHD (Fig. 14); the intermyofibrillar network loses its orderly arrangement and swirls, resembling the current in an eddying stream. These changes may be seen in several diseases but tend to be much more common in the myopathies ***(Jeffrey et al., 2008).***

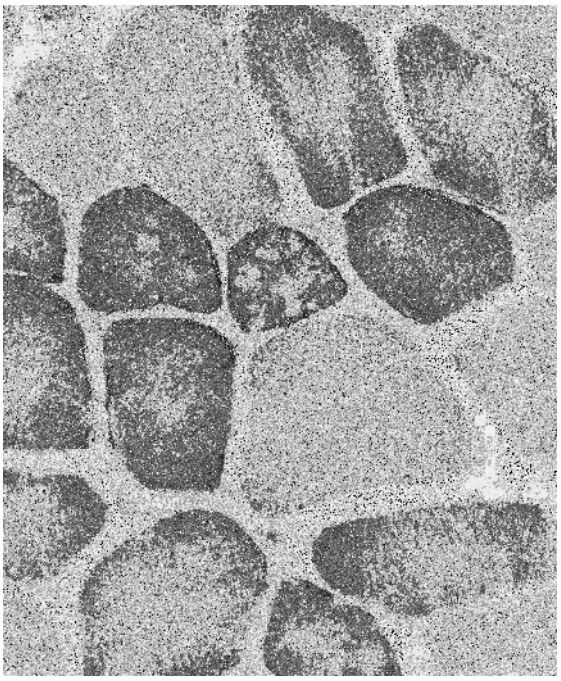

Fig. (14): Myopathy: Moth-eaten, whorled fibers. The intermyofibrillar network pattern is distorted, and some areas lack the proper stain (nicotinamide adenine dinucleotide dehydrogenase stain) ***(Jeffrey et al., 2008).***

Other Changes:

Selective changes in fiber types occur. Type 2 fiber atrophy is one of the most common abnormalities seen in muscle (Fig. 15). Type 2 atrophy, particularly if limited to type 2B fibers, is nonspecific and indicates a muscle that is subject to disuse. If a limb is casted and the muscle examined some weeks later, selective atrophy of type 2 fibers is noted. Any chronic systemic illness tends to produce type 2 atrophy. It occurs in rheumatoid arthritis, nonspecific collagen vascular diseases, cancer (hence the name *cachectic atrophy*), mental retardation in children, and pyramidal tract disease. Type 2B

fiber atrophy can also result from chronic corticosteroid administration. Therefore, type 2 fiber atrophy should probably be regarded as a nonspecific result of anything less than robust good health ***(Moghadaszadeh et al., 2001).***

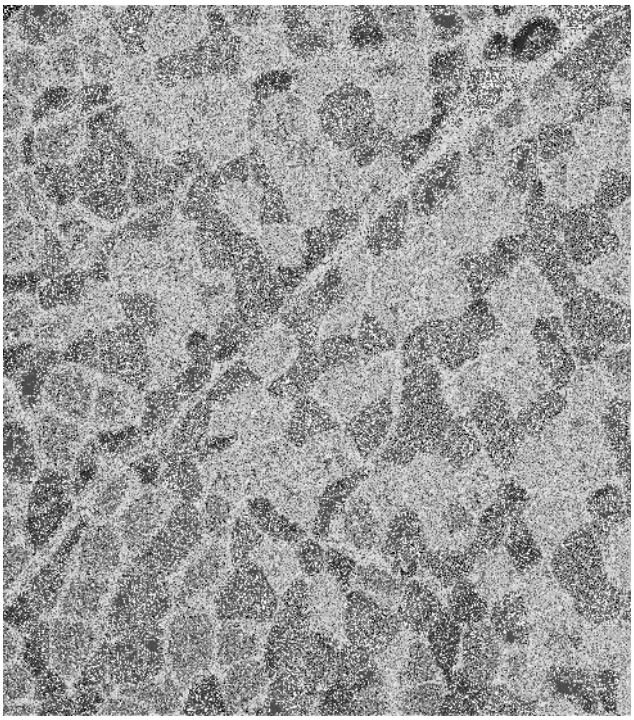

Fig. (15): Type 2 fiber atrophy is a common change of disuse atrophy or steroid myopathy (myosin adenosine triphosphatase stain) ***(Moghadaszadeh et al., 2001).***

Type 1 fiber atrophy is more specific. It occurs in some of the congenital nonprogressive myopathies, such as nemaline myopathy and congenital fiber type disproportion, and is characteristic of myotonic dystrophy. Changes in the proportion of fibers in the biopsy are quite separate from changes in the fiber size. The name *fiber type predominance* refers to a change

in the relative numbers of a particular fiber type. Type 1 fiber predominance is a normal finding in the gastrocnemius and deltoid muscles. It is also the hallmark of congenital myopathies and many of the early dystrophies. Type 2 fiber predominance is seen in the lateral head of the quadriceps muscle. Type 2 predominance occurs occasionally in juvenile spinal muscular atrophy and motor neuron disease but is not firmly associated with any particular disease condition ***(Greenberg et al., 2006).***

Muscular dystrophies of limb girdle and Xp21 (Duchenne and Becker) type show an increase in the normal variability of fibre size, necrosis, regenerating fibres, fibre splitting, increased numbers; of central nuclei, and an increase in fibrous tissue (Fig. 16) ***(Dent et al., 2005).***

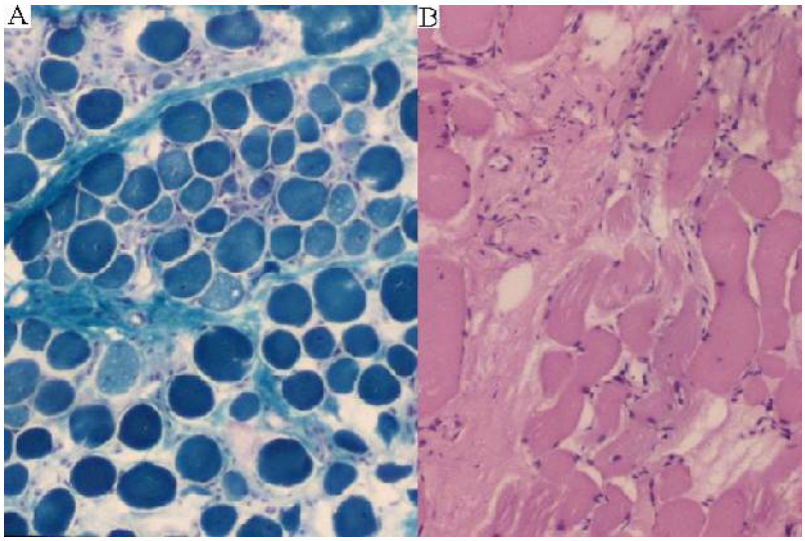

Fig. (16): Dystrophic muscle (A = Gomori trichrome; B = hematoxylin and eosin [H&E] stain) ***(Dent et al., 2005).***

Immunocytochemistry shows dystrophin to be absent in Duchenne and reduced in Becker muscular dystrophy (Fig. 17) ***(Michelle et al., 2009)***

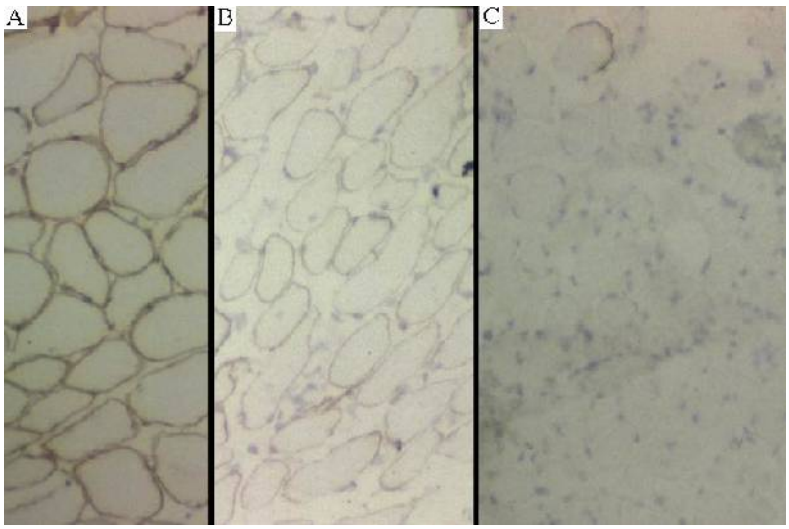

Fig. (17): (A) Normal dystrophin staining. **(B)** Intermediate dystrophin staining in a patient with Becker muscular dystrophy. **(C)** Absent dystrophin staining in a patient with Duchenne muscular dystrophy ***(Michelle et al., 2009).***

In FSHD, a biopsy of an affected muscle shows the features of dystrophy described previously, along with the presence of lobulated fibers seen best on oxidative stains. There also are increased subsarcolemmal accumulations of mitochondria ***(Bertorini and Horner, 2002).***

In myotonic dystrophy (Steinert disease or DM1), the muscle biopsy shows predominant type I fiber atrophy, scattered pale muscle fibers, excessive internal nucleation that may occur in chains, and frequent ring fibers and sarcoplasmic masses. Pyknotic fibers also can be seen later in this disease, which is atypical for primary myopathic conditions. Another form of myotonic myopathy is the proximal myotonic variant (PROMM or DM2): the histologic features are dominated by type II rather than type I atrophy; ring and chain fibers are less pronounced than in myotonic dystrophy; and pyknotic fibers are not present ***(Bertorini and Horner, 2002).***

In Emery-Dreifuss muscular dystrophy, the biopsy shows features described previously, but the proliferation of the connective tissue tends to be extensive. This accounts for the muscle contractures observed early in this disease. Staining for emerin is useful in the diagnosis of this X-linked recessive type of this dystrophy ***(Sabina et al., 2000)***

In dermatomyositis, the pathognomonic histologic feature is perifascicular atrophy (Fig. 18). The perifascicular area contains small regenerating and degenerating fibers.

Oxidative enzyme stains highlight the microvacuolation within these fibers. Scattered necrotic fibers and wedged-shaped microinfarcts may be evident ***(Greenberg et al., 2005).***

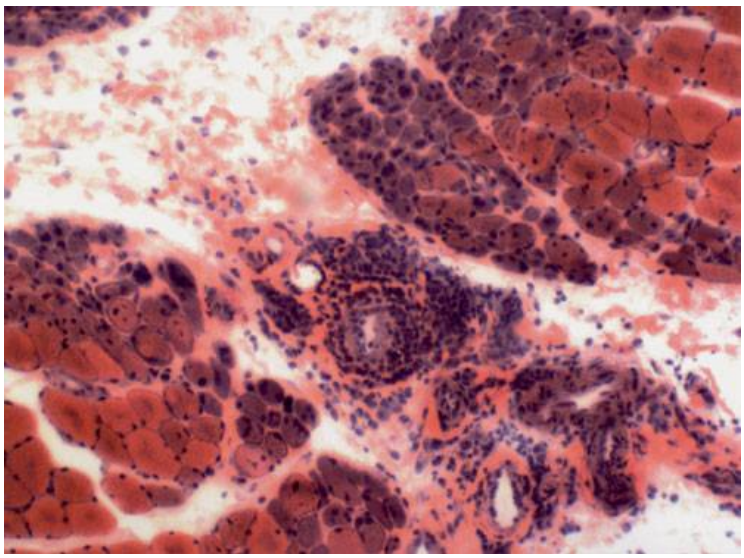

Fig. (18): Dermatomyositis. Muscle biopsy demonstrates classic perifascicular atrophy of muscle fibers and perivascular inflammation within the perimysium. (H&E) ***(Greenberg et al., 2005)***.

The histologic features of Polymyositis (PM) are distinct from dermatomyositis. The predominant histologic features in PM are variability in fiber size, scattered necrotic and regenerating fibers, and inflammatory cell infiltrate (Fig. 19) ***(Anthony and James, 2008).***

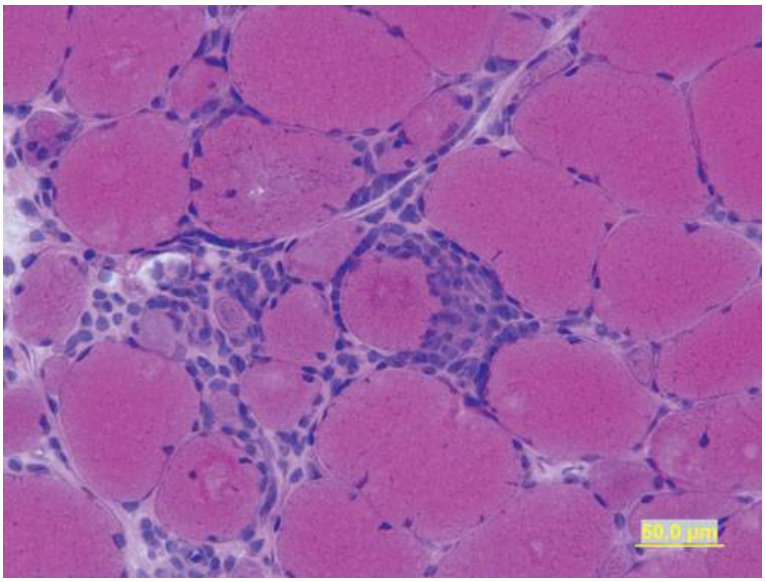

Fig. (19): Polymyositis. Muscle biopsy demonstrates endomysial mononuclear inflammatory cell infiltrate surrounding and invading non-necrotic muscle fibers. H&E ***(Anthony and James, 2008).***

Congenital myopathies

(1) Central core myopathy(CCD):

The characteristic histological features are the structural alterations within the center of muscle fibers. These cores appear only in type 1 muscle fibers and are particularly noticeable on nicotinomide adenine dinucleotide tetrazolium reductase (NADH-TR) stains where these regions are devoid of stain (Fig.20) ***(Quinlivan et al., 2003).***

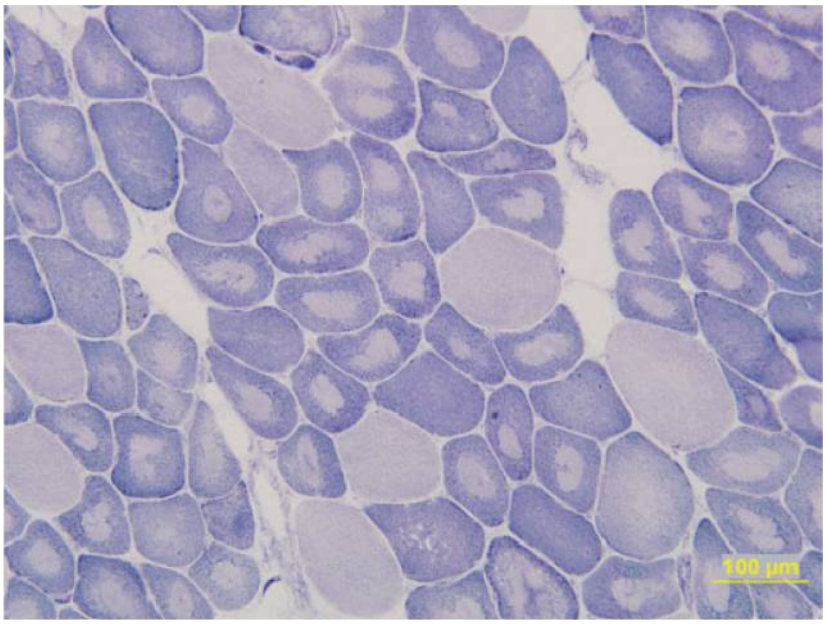

Fig. (20): Central core myopathy. (NADH-TR) stain demonstrates areas devoid of oxidated enzyme activity in the center of the fibers or sometimes eccentric regions ***(Quinlivan et al., 2003).***

(2) Multi/Minicore Myopathy(MmD):

Muscle biopsies reveal multiple small regions within muscle fibers of variable size (minicores) formed by disorganization of the myofibrils (Fig. 21). These minicores are similar to central cores but are much smaller and do not extend the entire length of the muscle fiber as do central cores ***(Ferreiro and Fardeau, 2002).***

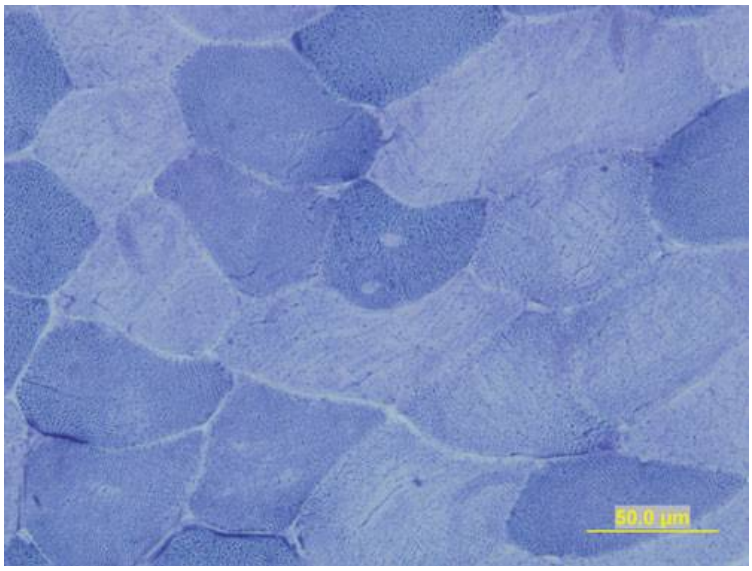

Fig. (21): Multi/minicore myopathy. NADH stain demonstrates small areas devoid of oxidative enzyme activity ***(Ferreiro and Fardean, 2002).***

(3) Nemaline myopathy:

On routine histochemistry, the nemaline rods are best appreciated on modified Gomori-trichrome stain, on which the rods appear as small, red-staining bodies in the subsarcolemma and occasionally perinuclear regions (Fig. 22). On EM, the typical "rod bodies" measure 3–6 µm in length and 1–3 µm in diameter, giving the appearance of threads (nemaline: Greek for "thread like"). The nemaline rods have a density similar to the Z-disk (Fig. 23) ***(Wallgren-Pettersson, 2005).***

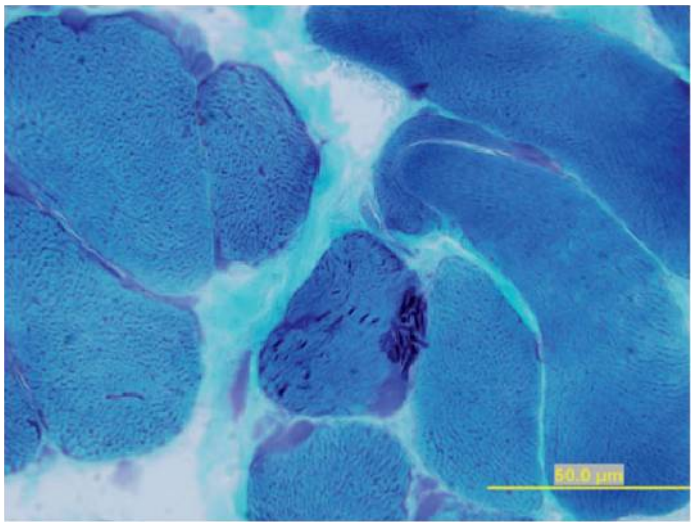

Fig. (22): Nemaline myopathy ***(Wallgren-Pettersson, 2005).***



Fig. (23): Nemaline myopathy. Electron microscopy reveals rods appearing as osmiophilic bodies, which have the same density as the Z-disks ***(Wallgren-Pettersson, 2005).***

(4) Centronuclear myopathy:

Muscle biopsies reveal myonuclei in the center of muscle fibers, often forming chains when viewed longitudinally. Occasionally, the nuclei cluster in the center of the fiber rather than forming longitudinal chains (Fig. 24) ***(Jeannet et al., 2004).***

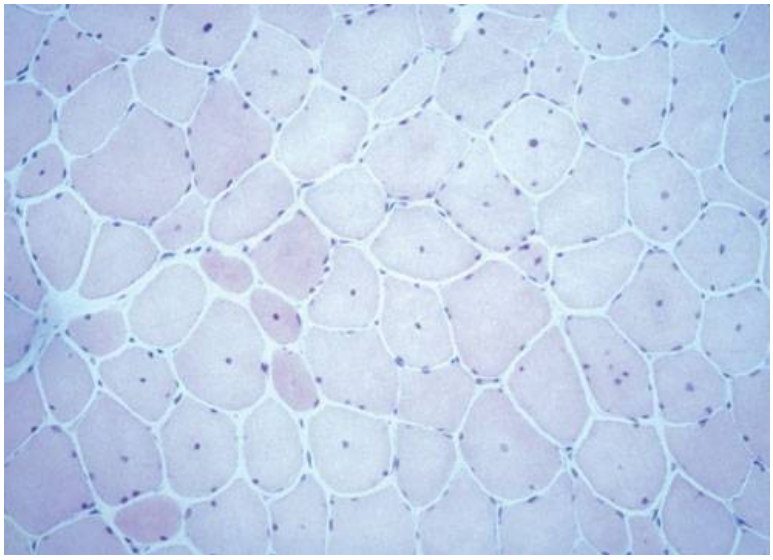

Fig. (24): Centronuclear myopathy. Increased number of internalized nuclei often in the center of the muscle fiber is appreciated ***(Jeannet et al., 2004).***

(5) Congenital fiber-type disproportion:

Muscle biopsies reveal a disproportion in the size of type 1 compared to type 2 fibers. While type 1 fibers are more numerous, they are typically less than 15% the diameter of type

2 fibers, which appear normal in size or slightly hypertrophic (Fig. 25) ***(Anthony and James, 2008).***

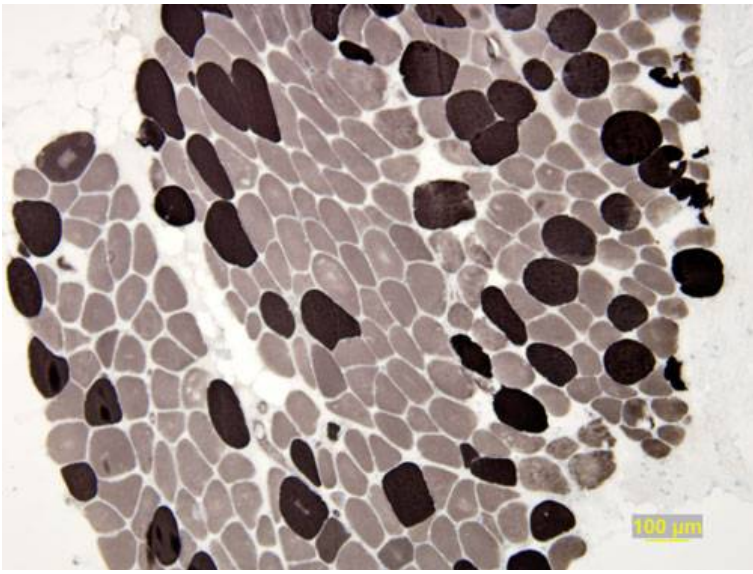

Fig. (25): Congenital fiber-type disproportion. Type 1 fibers are more numerous but smaller in diameter than the type 2 fibers ***(Anthony and James, 2008).***

(6) Sarcotubular myopathy:

Muscle biopsy revealed increase in internal nuclei, muscle fiber splitting, and many fibers (mostly type 2) with small vacuoles ***(Schoser et al., 2005).***

(7) Fingerprint body myopathy:

Muscle biopsy reveals type 1 fiber predominance with type 1 fiber hypotrophy and type 2 fiber hypertrophy ***(Anthony and James, 2008).***

Molecular genetics and pathogenesis of certain myopathies:

Dystrophinopathies:

Dystrophin is a structural protein, which is intimately bound to the sarcolemma and provides structural integrity to the muscle membrane (Fig. 26) ***(Cohn and Campbell, 2000).***

Abnormal quantity or quality of dystrophin results in the muscle losing its ability to maintain its integrity during contraction, leading to membrane tears and subsequent muscle fiber necrosis. The dystrophin gene, located on chromosome Xp21, is composed of approximately 2.4 megabases of genomic DNA and includes 79 exons, which code for a 14-kb transcript ***(Anthony and James, 2008).***

The large size of the gene probably accounts for the high spontaneous mutation rate responsible for one-third of new cases. Large deletions, several kilobases to over 1 million base pairs, can be demonstrated in approximately two-thirds of patients with dystrophinopathy. Approximately 5–10% of DMD cases are caused by point mutations, resulting in premature stop codons ***(Prior et al., 1995).***

Duplications are evident in another 5% of cases. Mutations occur primarily in the center (80%) and near the amino terminal (20%) of the gene ***(Prior et al., 1995).***

Mutations that disrupt the translational reading frame of the gene lead to near total loss of dystrophin and DMD, while in-frame mutations result in the translation of semifunctional dystrophin of abnormal size and/or amount and in outlier or BMD clinical phenotypes ***(Hoffman et al., 1988).***

Although there are exceptions to the "reading-frame rule," 92% of phenotypic differences are explained by in-frame and out-of-frame mutations ***(Prior et al., 1995).***

The clinical severity does not appear to correlate with the location of mutations in DMD. It appears that the quality or remaining functional capability of the mutated dystrophin protein is more important than the actual quantity. The reduction in the various sarcoglycans, which is also evident on immunohistochemical studies of DMD and BMD, suggests that normal dystrophin is important for the integrity of the sarcoglycan complex ***(Anthony and James, 2008).***

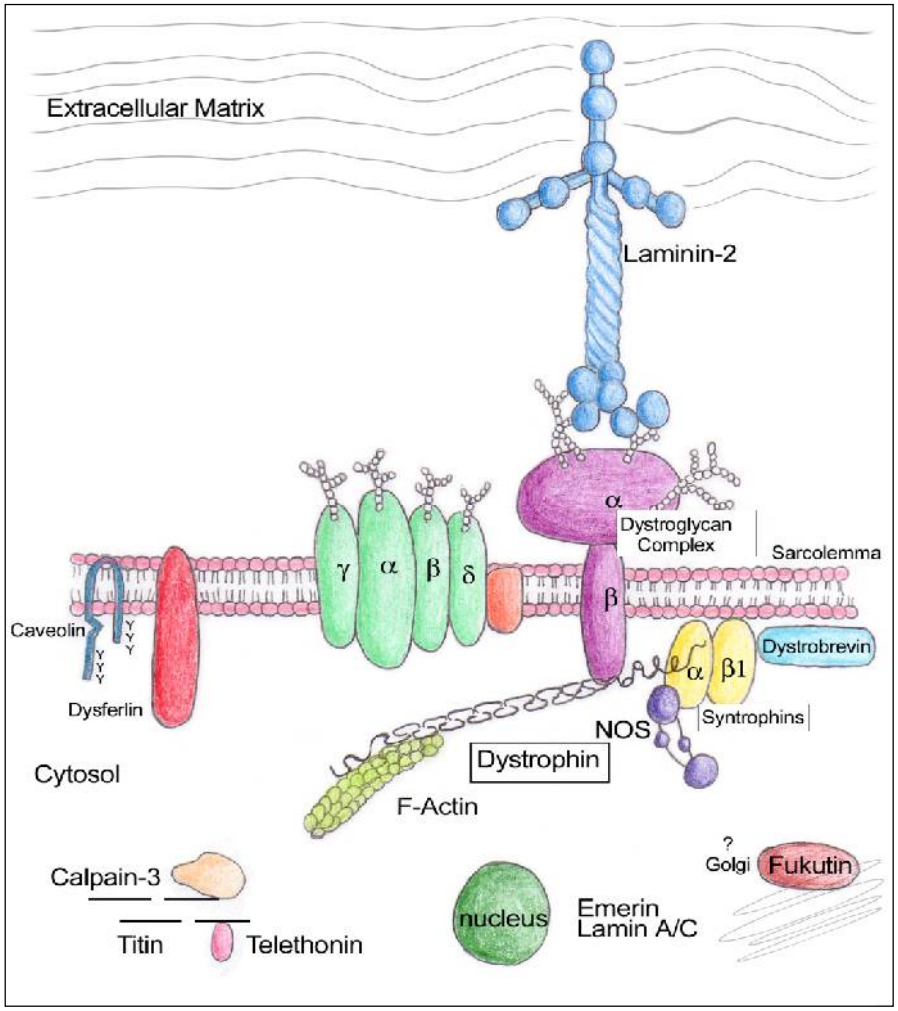

Fig. (26): The molecular organization of integral and peripheral components of the dystrophin-glycoprotein complex and novel proteins involved in muscular dystrophy in skeletal muscle ***(Anthony and James, 2008).***

Myotonic Dystrophies (DM1):

DM1is caused by an expansion of unstable polymorphic cytosine–thymine–guanine (CTG) trinucleotide repeats in the 3rd_ untranslated region of the myotonin protein kinase (DMPK) gene on chromosome 19q13. This CTG repeat is copied in the

gene up to 27 times in normals, but 50 to more than 4000 copies are found in DM1 patients. The severity of the myopathy directly correlates with the size of the CTG repeat, which is unstable ***(Meola, 2000).***

Inflammatory myopathies:

The cause of inflammatory myopathies is unknown, but the tissue injury is most likely mediated by immunological mechanisms. Capillaries seem to be the principal targets in dermatomyositis. Deposits of antibodies and complement are present in small blood vessels, and are associated with foci of myocyte necrosis. B cells and CD4+ T cells are present within the muscle, but there is a paucity of lymphocytes within the areas of myofiber injury. The perifascicular distribution of myocyte injury also suggests a vascular pathogenesis ***(Charles et al., 2009).***

In contrast, polymyositis seems to be caused by cell mediated injury of myocytes. CD8+ cytotoxic T cells and macrophages are seen near damaged muscle fibers, and the expression of HLA class I and class II molecules is increased on the sarcolemma of normal fibers. Similar to other immune-mediated diseases, antinuclear antibodies are present in a variable number of cases, regardless of the clinical category The specificities of autoantibodies are quite varied, but those directed against transfer RNA synthetases seem to be more or less specific for inflammatory myopathies ***(Mimori et al., 2007).***

The pathogenesis of inclusion body myositis (IBM) is less clear. As in polymyositis, CD8+ cytotoxic T cells are found in the muscle, but in contrast to the other two forms of myositis, immunosuppressive therapy is not beneficial. Intracellular deposits of β-amyloid protein, amyloid β–pleated sheet fibrils, and hyperphosphorylated tau protein, features shared with Alzheimer disease, have drawn attention to a possible relationship to aging. The protein deposition may result from abnormal protein folding. The two hereditary forms of inclusion body myopathy have a similar morphology. The autosomal recessive form is caused by mutations in the *GNE* gene (encoding UDP-*N*-acetylglucosamine 2-epimerase/*N*-acetylmannosamine kinase), and the autosomal dominant form is caused by mutations in the gene encoding myosin heavy chain IIa ***(Askanas and Engel, 2007; Needham et al., 2007).***

Congenital myopathies:

1- Central core myopathy:

Central core myopathy is an autosomal-dominant disorder caused by mutations in the ryanodine receptor gene (RYR1) on chromosome 19q13.1 ***(Mathews and Moore, 2004).***

2- Multi/Minicore myopathy (MmD):

This is a genetically heterogeneic group of disorders. The absence of clear dominant transmission in any well established case and the presence of several consanguineous families

strongly suggest that MmD usually is an autosomal-recessive entity or secondary to spontaneous mutations ***(Ferreiro and Fardeau, 2002).***

3- Nemaline myopathy:

Nemaline rods arise secondary to a derangement of proteins necessary to maintain normal Z-disk structure. The myopathy is genetically heterogeneic, with mutations having been identified in the genes that encode for tropomyosin (TPM3), beta-tropomyosin (TPN2), nebulin (NEM2), troponin T (TnT1), and actin (ACTA1) ***(Laporte et al., 2000).***

4- Centronuclear myopathy:

There is genetic heterogeneity between the different forms of centronuclear myopathy. The severe X-linked neonatal form is caused by mutations in the myotubularin gene (MTM1) ***(Laporte et al., 2000).***

5- Congenital fiber-type disproportion:

Most cases are sporadic in occurrence, although there are some cases that appear to be inherited in an autosomal-dominant and others in an autosomalrecessive fashion ***(Anthony and James, 2008).***

6- Sarcotubular myopathy:

Mutations in TRIM 32, the gene encoding the tripartite motif-containing protein 32, have been demonstrated in two families; thus, this disorder is allelic to LGMD 2H ***(Schoser et al., 2005).***

7- Fingerprint body myopathy:

The pathogenic mechanism for the formation of the fingerprint bodies is not known ***(Anthony and James, 2008).***

Muscle Dystrophy

Introduction

Despite the rather complex range and classification of congenital and acquired neuromuscular disorders, the response that skeletal muscle makes to these conditions and insults is fairly narrow. This means that the changes that can be demonstrated in muscle using conventional imaging techniques are also limited ***(Mark and Andrew, 2008).***

Conventional radiographs have a limited role to play in the diagnosis of these conditions. Fat atrophy may be apparent on plain radiography while calcification within skeletal muscle can be seen both following trauma (as in myositis ossificans) and in inflammatory conditions such as dermatomyositis.

Hypertrophy and atrophy may be detected using ultrasonography (US), although when these changes are generalized they can be difficult to appreciate. US also has a role in guiding muscle biopsies. Fat infiltration is easier to recognize on US as the normal striated architecture of the muscle is lost and the affected muscles show an increase in reflectivity. The main disadvantage of US is its small field of view, which makes it a difficult tool for examining generalized muscle conditions.

CT has also been extensively used to distinguish patterns of selective muscle involvement in muscular dystrophies. Intramuscular fat infiltration is seen as an area of decreased muscular coefficient attenuation ***(Eugenio et al., 2007).***

The advent of muscle MRI, however, has almost completely replaced the use of CT. The main advantage of MRI compared to CT is that it does not require ionizing radiation and also allows the use of multiplanar scanning, which is particularly useful for patients with severe limb contractures who are unable to lie in the correct position during the examination. Furthermore, comparative studies using both CT and MRI techniques have shown that MRI has a higher sensitivity than CT for identifying early fatty replacement in muscles, and provides better anatomical details (Fig. 27) ***(Mark and Andrew, 2008).***

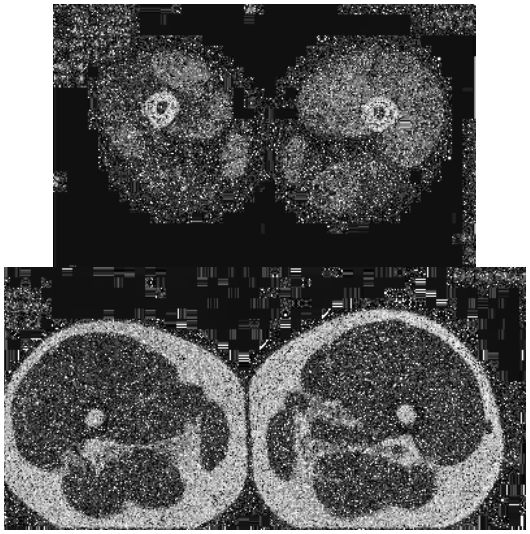

(a) **(b)**

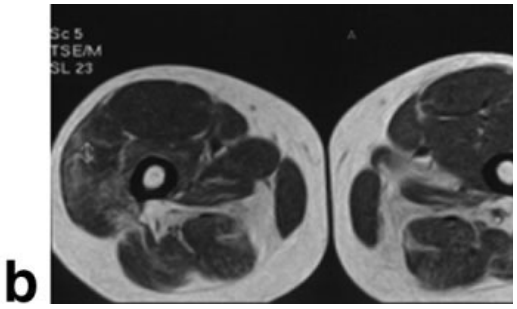

(c)

Figure (27): (a): A CT scan at the middle third of the thigh shows fat infiltration in the posterior muscular compartment, particularly relevant for the adductor magnus, and light involvement of the vastus lateralis m. The MR images **(b):** at the same level; **(c):** more proximal) show how the adipose substitution is almost complete for the right quadriceps in a more proximal portion ***(Mark and Andrew, 2008)***

The pattern of signal intensity does give some useful information about the chronicity of a muscle disorder. Fat infiltration represents a long-standing irreversible process, while oedema-like signal change represents acute or subacute

and potentially reversible muscle damage ***(Mark and Andrew, 2008).***

Technical Aspects

The main goal in MR imaging of abnormal skeletal muscles is the delineation of changes in tissue fat—water composition. T1-weighted imaging is essential for depicting high-signal-intensity fat and low-signal-intensity water. Short tau inversion recovery (STIR) sequences are sensitive for the detection of edematous processes and specific by suppression of signal from fat. Alternative T2-weighted chemical shift sequences offer sufficient fat suppression and relatively short scanning times. However, fast T2-weighted spinecho sequences should be avoided because they provide insufficient fat signal suppression. Gadolinium-enhanced T1-weighted sequences may be helpful in differentiating inflammatory or neoplastic lesions from edematous fluid ***(Wing et al., 2002).***

Coronal images provide the best overview of the longitudinal extent of the disease and allow identification of palpable bony landmarks. Axial images offer the best delineation of muscle groups and tissue characterization. Circumferential body coils with large fields of view are essential to compare symmetry of muscle involvement in the bilateral extremities. Surface coils are optional to maximize the signal-to-noise ratio for imaging selected areas. Sedation may be needed to prevent motion artifacts in infants and children. The total scanning time can be limited to 20 min ***(Wing et al., 2002).***

Muscular Dystrophies

DMD:

DMD is a rapidly progressive primary degeneration of skeletal muscle, with age at onset from 4 to 6 years and death at 10 to 20 years old. It is the most severe form of muscular dystrophy and is inherited as an X-linked recessive disorder, predominantly in boys. An increase of more than 10-fold in serum CK activity is noted in this disorder. Duchenne's muscular dystrophy is characterized by an initial symmetric and selective involvement of the proximal pelvic girdle muscles in the early stage of the disease process, and the calf and proximal shoulder girdle muscles in the late stage. Pseudohypertrophy of the calves is present in 80% of patients.

T1-weighted MR images reveal hyperintense fatty infiltration interspersed between the diseased muscles (fig. 28). The mean fat mass is significantly higher in diseased muscle than in normal muscle ***(*Leroy *et al., 1997).***

However, T2 and STIR imaging will show edema and/or signs of inflammation in other muscles that are spared of fatty infiltration, and have normal signal intensity on T1. These findings are of interest because they suggest that an inflammatory component, or a phase of necrosis with associated edema, plays a significant role in the early phases of muscle

damage before the muscle is replaced by fat or fibrotic tissue ***(Eugenio et al., 2007).***

MR imaging enables the radiologist to determine the severity of fatty infiltration, which parallels declination in muscle strength. The muscle in the thigh that is most resistant to disease is the gracilis, followed by the sartorius, semitendinous, and semimembranous muscles (Figs. 29 and30). Asymmetric involvement of the thigh muscles is not unusual. The most characteristic histologic features are the presence of hyaline fibers, adjacent parts of focal fiber necrosis, and ongoing phagocytosis ***(Wing et al., 2002).***



Fig. (28): Duchenne's muscular dystrophy in 12-year-old boy with 3-year history of unstable gait. Serum creatine kinase value was 4227 U/L. Coronal T1-weighted spin-echo MR image (TR/TE, 300/20) shows longitudinal

extent of fatty infiltration of pelvic girdle and thigh muscles ***(Wing et al., 2002).***

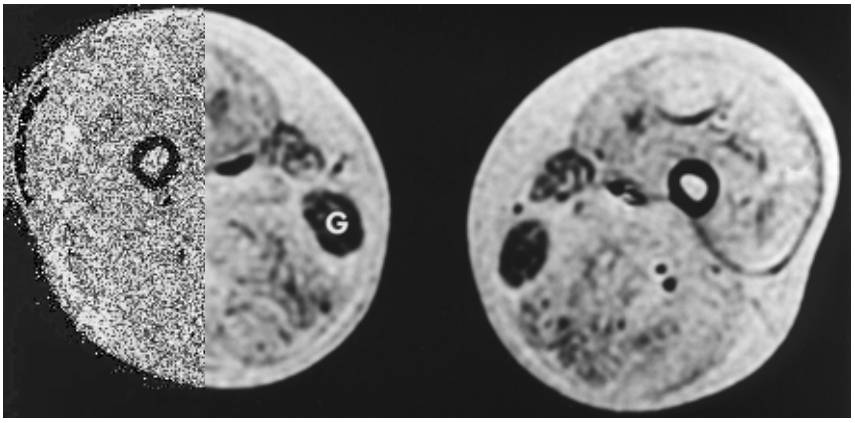

Fig. (29): Duchenne's muscular dystrophy in 11-year-old boy. Axial T1-weighted spin-echo MR image (TR/TE, 500/20) shows widespread bilateral fatty infiltration of thigh muscles, resulting in mosaic pattern. Bilateral gracilis muscles (G) are most resistant to disease ***(Wing et al., 2002).***

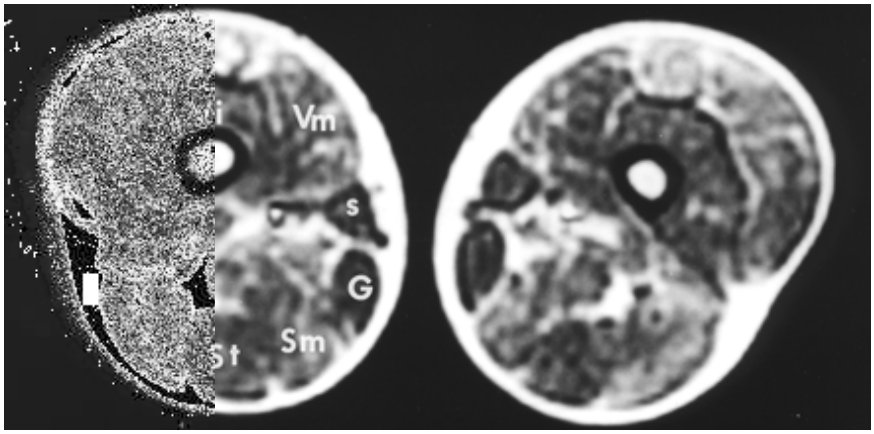

Fig. (30): Duchenne's muscular dystrophy in a 7-year-old boy, brother of patient in Figure 28. Axial T1-weighted spin-echo MR image (TR/TE, 500/20) shows moderate fatty infiltration with patchy pattern involving bilateral thigh muscles. Bilateral semimembranosus (Sm), vastus intermedius (Vi), and vastus medialis (Vm) muscles are less involved. Note sparing of bilateral gracilis (G), sartorius (s), and semitendinosus (St) muscles ***(Wing et al., 2002).***

BMD:

BMD is a slowly progressive primary degeneration of skeletal muscle, with an onset age of approximately 11 years and age at death up to the fourth decade. The disease is inherited as an X-linked recessive disorder, predominantly in boys. Duchenne's and Becker's muscular dystrophies affect the same dystrophin genetic system and have the same muscular involvement, but the Becker type is less severe. Symptoms appear in the lower limbs 5 to 10 years before they occur in the upper limbs. Serum CK activity in Becker's muscular dystrophy is raised to a degree similar to that found in the Duchenne type.

The selective muscular involvement in Becker's muscular dystrophy is apparent on T1-weighted MR images (Figs. 31, 32). The rectus femoris, adductor longus, gracilis, sartorius, semitendinosus, and semimembranous muscles are relatively spared and even hypertrophied in the thighs. Enlargement of the calves due to fatty infiltration (i.e., pseudohypertrophy) of the bilateral gastrocnemius and soleus muscles occurs in the Becker type, but it is less severe than in Duchenne's muscular dystrophy. The histology of Becker's muscular dystrophy resembles that of the Duchenne type, except that in the Becker type the hyaline fibers are relatively uncommon and regenerative fiber clusters are often seen ***(Wing et al., 2002).***

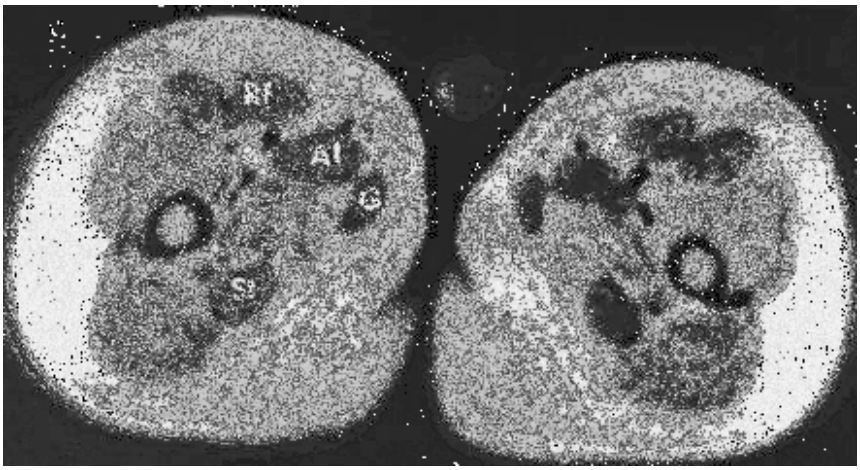

Fig. (31): Becker's muscular dystrophy in 13-year-old boy with proximal muscle weakness. Serum creatine kinase value was 7600 U/L. Axial T1-weighted spin-echo MR image (TR/TE, 400/20) of proximal thighs shows pattern similar to that in Duchenne's muscular dystrophy, except for less severe involvement of rectus femoris (Rf), adductor longus (Al), gracilis (G), and semitendinosus (St) muscles. Involvement of bilateral thigh muscles is symmetric ***(Wing et al., 2002).***

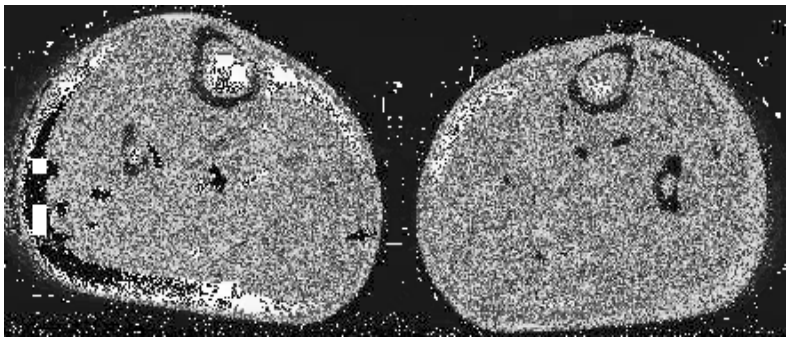

Fig. (32): Becker's muscular dystrophy in 13-year-old boy with proximal muscle weakness. Serum creatine kinase value was 7600 U/L. Axial T1-weighted spin-echo MR image (400/20) shows pseudohypertrophy of bilateral calf muscles. Note that fatty infiltration in bilateral gastrocnemius (*straight arrows*) and soleus (*curved arrow*) muscles is less severe in Becker's dystrophy than in Duchenne type, resulting in patchy pattern ***(Wing et al., 2002).***

Congenital Muscular Dystrophies *(CMDs):*

CMDs are a clinically and genetically heterogeneous group of disorders that present within the first few months of life, with hypotonia, muscle weakness, and dystrophic changes on muscle biopsy. Although no systematic studies have evaluated muscle MRI in all of the genetically recognized forms of CMD, a few recent studies have reported muscle MRI findings in the most common forms of CMD, and in particular the form secondary to mutations in the collagen VI genes (Ullrich CMD) and the differential diagnosis with other forms of CMD with an overlapping phenotype ***(Eugenio et al., 2007).***

Patients with Ullrich CMD show diffuse involvement of all the posterior and lateral muscles of the thigh with selective sparing of the sartorius, gracilis, and adductor longus, and often the rectus femoris ***(Mercuri et al., 2005).***

In these patients there is also a typical appearance of increased signal at the periphery of the muscles with a relative preservation of the internal part of the muscle that is more obvious in the gastrocnemii and soleus at calf level and in the vasti muscles in the thigh. The rectus femoris often shows an "internal shadow" that can also be appreciated on US. These signs have a significant overlap with those observed in Bethlem myopathy, a milder dominant condition that is allelic to Ullrich CMD.

This pattern differs from that observed in another form of CMD with a significant clinical overlap. Patients with RSMD1, a condition that is secondary to deficiency in selenoprotein 1, also have rigidity of the spine, early respiratory involvement, and normal or only mildly elevated CK, but have a different muscle involvement on MRI ***(Eugenio et al., 2007).***

In patients with Ullrich CMD, the posterior and lateral muscles of the thigh are generally affected but the anterior-medial muscles, including the sartorius and gracilis, are spared. However, in RSMD1 the posterior-lateral muscles are usually less affected, and the sartorius muscle, which spared in Ullrich CMD, is always affected. Another important difference is that patients with RSMD1 do not show the typical appearance of more severe involvement of the peripheral portion of individual muscles that is observed in patients with Ullrich CMD (Fig. 33) ***(Mercuri et al.,2005).***

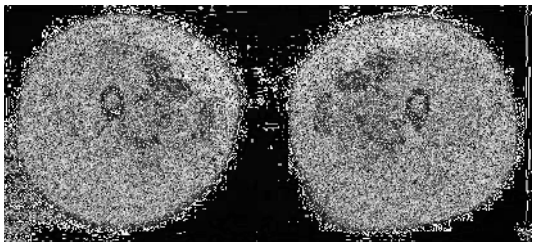

(a)



(b)

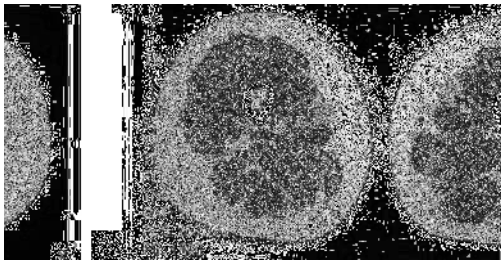

(c)



(d)

Fig. (33): MRI T1 transverse images patients with Ullrich CMD (**a** and **b**) and with RSMD1 (**c** and **d**). Note the diffuse involvement in the Ullrich patient with selective sparing of sartorius, gracilis, and adductor longus **(a).** The RSMD1 patient in contrast has selective involvement of the soleus muscle **(c).** At calf level the Ullrich patient shows a rim of increased signal between gastrocnemii and soleus **(b)** that is not present in the RSMD1 patient **(d)** ***(Mercuri et al., 2005).***

LGMDs:

LGMDs are a genetically heterogeneous group of disorders that are characterized clinically by predominant proximal muscle weakness affecting mainly the hip girdle, elevated creatinine kinase levels, and dystrophic changes on muscle biopsy. Recent advances in molecular genetics have led to the identification of a number of different forms, and a biochemical classification was recently proposed. Based on the pattern of inheritance, LGMDs are divided into autosomal-dominant (LGMD1, A–E) or autosomal-recessive (LGMD2, A–J) forms. The autosomal-recessive forms are more common, with a cumulative prevalence of 1:15,000. The two most frequent forms are LGMD2A (due to mutations in the calpain gene) and LGMD2I (due to mutations in the FKRP gene). Both conditions are autosomal-recessive. A few recent studies have reported distinct muscle MRI patterns in patients with different forms of LGMD ***(Eugenio et al., 2007).***

Patients with LGMD2A show a striking and early involvement of the posterior thigh muscles. There is predominant involvement of the adductors and semimembranosus muscles in young patients, with minimal functional motor impairment and a more diffuse involvement of the posterolateral muscles of the thigh and the vastus intermedius with relative sparing of the vastus lateralis, sartorius, and gracilis in patients with restricted ambulation ***(Mercuri et al., 2005).***

At the calf level, patients show involvement of the soleus muscle and the medial head of the gastrocnemius, with relative sparing of the lateral head. Patients affected by LGMD2I show some overlap but also some differences with the pattern of muscle involvement observed in patients with LGMD2A ***(Fischer et al., 2005).***

At the thigh level, patients with LGMD2A and LGMD2I both have predominant involvement of the adductor magnus and the posterior thigh muscles; however, there is more substantial involvement of muscles of the anterior compartment in LGMD2I, and a significant hypertrophy of the sartorius and gracilis muscles. At the calf level, patients with LGMD2I have variable involvement of the calf muscles, with predominant involvement of the posterior muscles, but without the striking differential involvement between the medial and the lateral head of the gastrocnemius observed in LGMD2A. The typically atrophic phenotype observed in LGMD2A is a diagnostic feature that can be used to differentiate that condition from LGMD21, which is typically associated with muscle hypertrophy (Fig. 34).

Another study described MRI and Magnetic resonance spectroscopic (MRS) findings from calf muscles in patients affected by LGMD characterized by deficiency of proteins of the sarcoglycan complex. T1 and T2W images showed marked changes in the soleus with only minimal changes in the gastrocnemii muscles. However, at variance with the other

recently described forms of LGMD, patients with sarcoglycan deficiency had more prominent involvement of the anterior muscles, with abnormal signal in both the tibialis anterior and peroneal muscles. This is in keeping with a previous clinical observation of significant foot dorsiflexion weakness in patients with sarcoglycanopathies ***(Eugenio et al., 2007).***

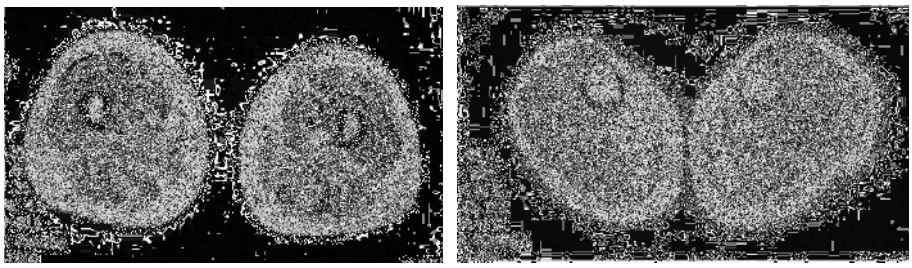

(a) **(b)**

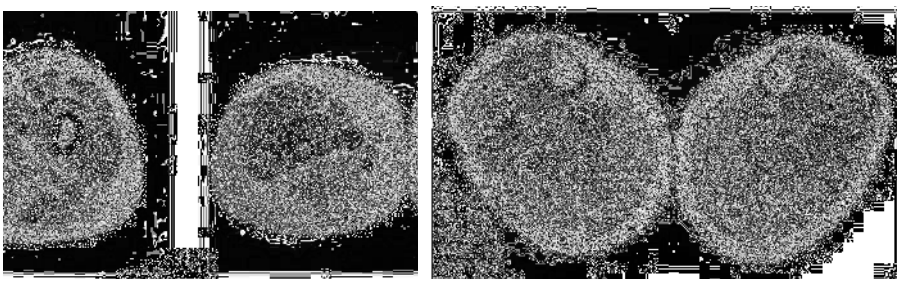

(c) **(d)**

Fig. (34): MRI T1 transverse images in (**a** and **b**) a patient with LGMD2A (mutations in the calpain gene), and (**c** and **d**) a patient with LGMD2I (mutations in the FKRP gene). Note that both forms have a predominant involvement of the adductor magnus and posterior muscles of the thighs with different involvement of the gracilis. At calf level, both forms have a predominant involvement of the posterior muscles. However, while the patient with LGMD2I has involvement of both gastrocnemii **(d),** the patient with LGMD2A has involvement of the gastrocnemius medialis and relative sparing of the lateralis **(c)** ***(Eugenio et al., 2007).***

Emery Dreifuss MD

Emery-Dreifuss MD is characterized by slowly progressive weakness and early contractures of the elbows and Achilles tendons, with rigidity of the spine and invariable cardiac involvement. There are two modalities of inheritance: X-linked recessive (EDMD), in which the defective gene is emerin, and autosomal-dominant (EDMD2), in which the defect lies in the lamin A/C gene. Both emerin and lamins are proteins of the nuclear envelope, and EDMD2 is at least five times more common than EDMD ***(Eugenio et al., 2007).***

It has been recently reported that muscle MRI can help to identify distinct patterns of muscle involvement in the two forms**.** While patients with the X-linked form have minimal involvement at thigh level, patients with the dominant form often have a moderate to severe selective involvement of the vastus lateralis and intermedius, which in some cases is associated with involvement of the adductor magnus. The difference between the two forms is more striking at calf level: patients with the X-linked form have preferential involvement of the soleus muscle, while patients with the dominant form have a striking differential involvement between the medial head of the gastrocnemius, which is always predominantly involved with relative sparing of the lateral head. This pattern is more obvious in mildly affected patients in whom the other calf muscles are spared or only mildly involved, but is also recognizable in patients with more advanced disease ***(Mercuri et al., 2002).***

Muscle MRI can also help the investigator suspect the dominant form of EDMD by identifying an abnormal distribution of body fat. Allelic mutations in the lamin A/C gene are also responsible for a dominantly inherited partial lipodystrophy of the Dunningan type, and a number of cases with muscle involvement and signs of partial lipodystrophy have been reported. Apart from these clearly overlapping cases, careful evaluation of muscle MRI in EDMD2 may also show minor abnormalities of fat distribution. EDMD2 patients, especially those who are severely affected, tend to accumulate fat in the neck and the abdomen but have very little fat in the subcutaneous tissue of the limbs. In some cases, extremely reduced fat around the limbs can also be observed in young patients with mild muscle involvement (Fig. 35) ***(Eugenio et al., 2007).***

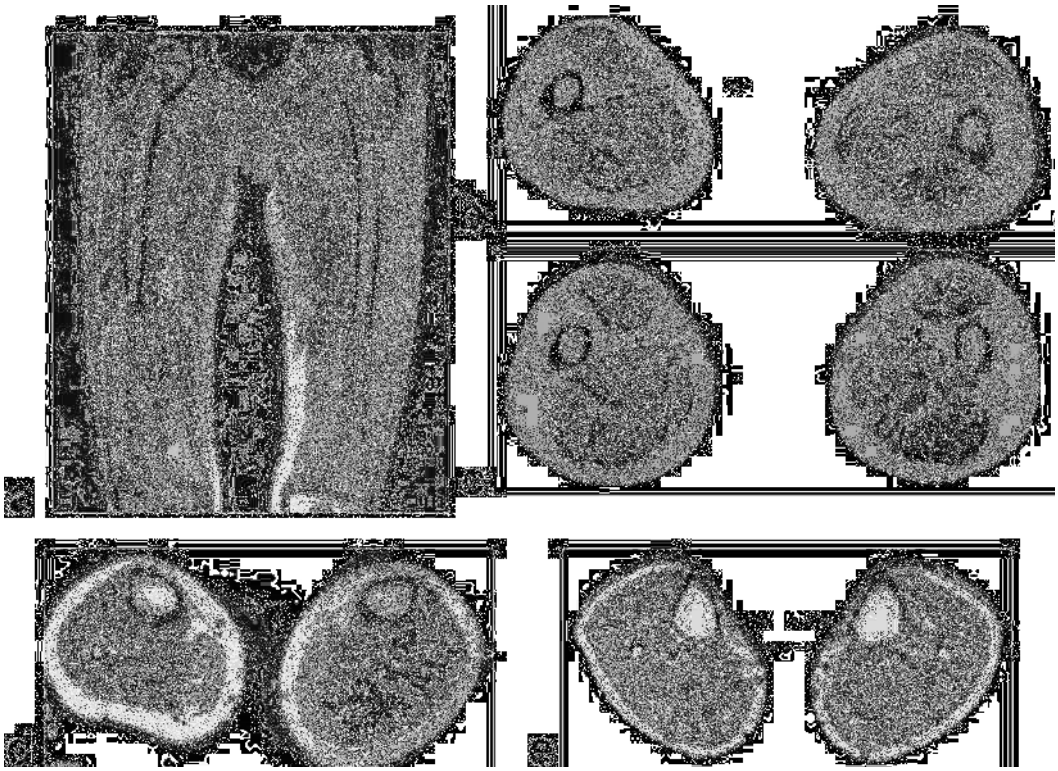

Fig. (35): Dominant form of Emery Dreifuss MD. **a:** A T1 coronal image shows selective involvement of the anterolateral muscles of the thigh and sparing of the medial muscles. **b:** This can be better visualized on T1 transverse images showing a selective involvement of the vastus lateralis with sparing of the rectus femoris and the postero-medial muscles. **c:** The same pattern can be observed in another patient. **d** and **e:** At calf level there is selective involvement of the medial head of the gastrocnemius (note in part d the thin rim of subcutaneous fat) ***(Eugenio et al., 2007).***

Myotonic muscular dystrophy (DM)

Myotonic muscular dystrophy is inherited as an autosomal dominant trait. The disease affects several organ systems and is characterized by myotonia, weakness and wasting of muscles, Cataract, cardiac abnormalities, and testicular atrophy. Two types of myotonic muscular dystrophy (DM) are recognized type 1 and type 2 (proximal myotonic myopathy, PROMM) ***(Day et al., 2003).***

DM type I is the most common adult-onset form of muscular dystrophy. DM has been well characterized using MRI. Common findings include increased thickness of the subcutaneous fat associated with a decrease in muscle thickness. The sternocleidomastoid muscle is affected early in the disease course and demonstrates striking atrophy. Other distal muscles, such as the tibialis anterior and other foot dorsiflexors, also may be affected early. Later in the disease course, atrophy develops elsewhere, including the triceps, the extensor muscles of the spine, and the medial head of the gastrocnemius. The lateral head of the gastrocnemius muscle and the soleus become involved later and to a lesser extent. Proximal musculature also may demonstrate fatty infiltration (Fig. 36). For unknown reasons, the sartorius and gracilis muscles frequently are spared ***(Calado et al., 2000).***

Proximal myotonic myopathy (PROMM, DM type II) has many features in common with DM type I, but it is more likely to present with muscle stiffness, weakness, and pain. Although distal weakness can occur, weakness usually is more severe proximally. Calf pseudohypertrophy may occur. DM type I is the result of an expansion in the myotonin protein kinase gene; DM type II is the result of an expansion of the zinc finger protein 9 gene (ZFN9). Although the underlying pathogenesis of both conditions remains unclear, it is hypothesized that the repeat sequence expansion results in alterations in RNA. MRI in a patient who had a proved expansion of the ZFN9 gene revealed increased T1-weighted hyperintensities indicative of fatty deposition (see Fig. 36) ***(Day et al., 2003).***

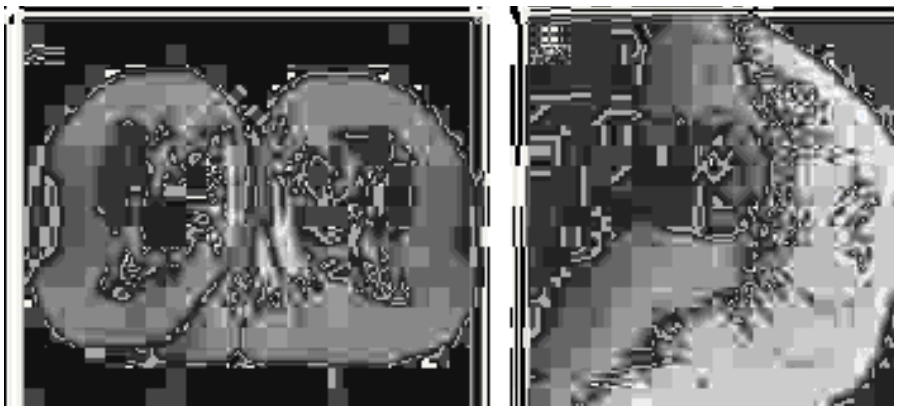

Fig. (36): (Left) Patient who had genetically proved DM type II (ZFN9 mutation) displaying mild hyperintensities on T1-weighted imaging indicative of fatty deposition. The vastus lateralis and posterior thigh muscles are more involved. (Right) Patient who had DM type 1 displaying striking fatty infiltration of the shoulder girdle musculature on T1-weighted imaging ***(Day et al., 2003).***

Inflammatory Myopathies

Inflammatory myopathies can be classified as idiopathic or secondary. Idiopathic inflammatory myopathies encompass a group of heterogeneous muscle diseases that share the clinical features of slowly progressive weakness of skeletal muscles and muscle fatigue ***(Maximilian et al., 2009).***

Polymyositis

Polymyositis is a rare autoimmune and sometimes paraneoplastic inflammatory myositis. The diagnosis is based on a typical clinical presentation, elevated serum skeletal muscle enzymes, and findings on electromyography and muscle biopsy. MRI accurately documents the extent and intensity of the muscle abnormalities. The inflammation is usually symmetric and classically involves the proximal muscle groups**,** but muscle involvement can also be patchy and asymmetric (Fig. 37). High signal intensity is seen in the active phase on STIR and fat-saturated gadolinium-enhanced T1-weighted images. Sometimes inflammation may extend only along or around individual muscles and muscle groups (myofascial distribution) (Fig. 38). In the chronic phase, fatty atrophy of the musculature is seen on T1-weighted images (Fig. 39) ***(Maximilian et al., 2009).***

Chest radiography and high-resolution CT scanning of the chest are helpful for evaluation of interstitial lung disease. Barium swallow studies are helpful for evaluation of dysphagia or dysphonia. Mammography and pelvic US is considered in screening for associated malignancy. Testing for associated malignancy is based on age and sex and may also include upper and lower gastrointestinal endoscopy ***(Ramesh and* Ramesh, *2009).***

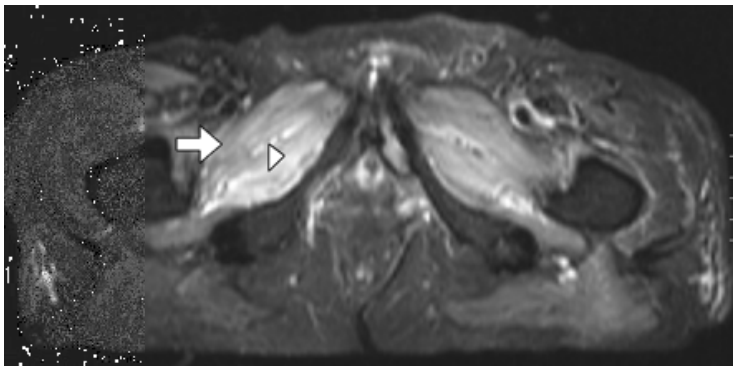

Fig. (37): 64-year-old man with polymyositis. Note diffuse edema and inflammation of obturator externus (*arrowhead*) and pectineus (*arrow*) muscles on axial STIR image ***(Maximilian et al., 2009).***

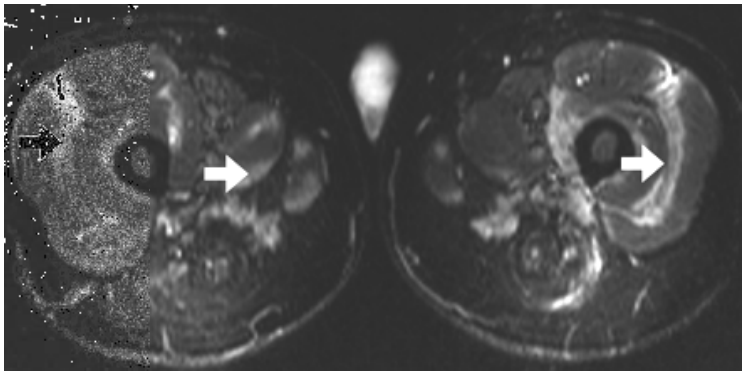

Fig. (38): 40-year-old man with anti-signal recognition particle polymyositis. Note myofascial orientation of edema and inflammation on axial STIR image (arrows) ***(Maximilian et al., 2009).***

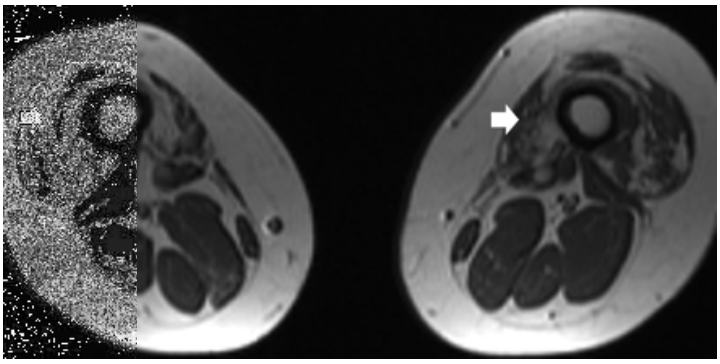

Fig. (39): 55-year-old woman with chronic polymyositis. Note advanced fatty atrophy, especially of quadriceps muscles (arrows), on unenhanced axial T1-weighted image ***(Maximilian et al., 2009).***

Dermatomyositis:

In dermatomyositis, the subcutaneous connective tissue septa and sometimes even the muscle fasciae are also involved (Fig. 40). Juvenile dermatomyositis generally takes a more severe clinical course, which is reflected by the extent and intensity of cutaneous, subcutaneous, and muscular signal abnormalities on MRI (Fig. 41).

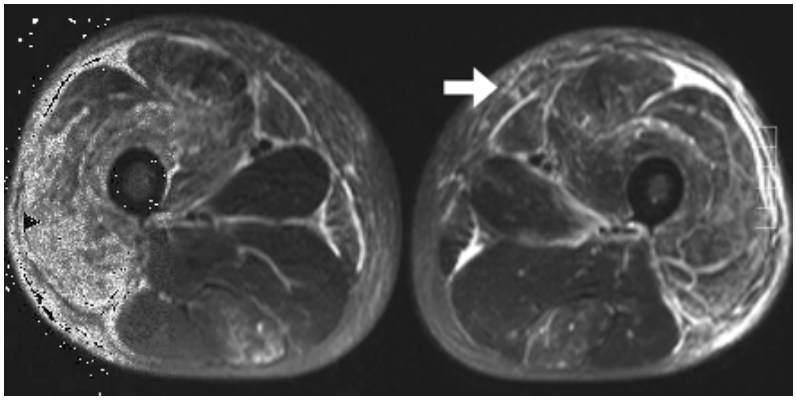

Fig. (40): 42-year-old man with known dermatomyositis. Axial STIR image shows diffuse hyperintensity in some thigh muscles (arrowhead, vastus lateralis muscle). Note also increased signal in subcutaneous tissue septa (arrow) and skin thickening ***(Maximilian et al. 2009).***



Fig. (41): 14-year-old girl with known juvenile dermatomyositis. Whole-body STIR image shows multifocal patchy pattern of muscle edema and inflammation (arrows) ***(Maximilian et al. 2009).***

Paraneoplastic dermatomyositis:

There is an increased incidence of cancer ranging from 6% to 45% in dermatomyositis. The association with cancer has not been demonstrated in juvenile dermatomyositis and the increased risk is predominantly seen in adults over the age of 40 years (Fig 42) ***(Anthony and James, 2008).***

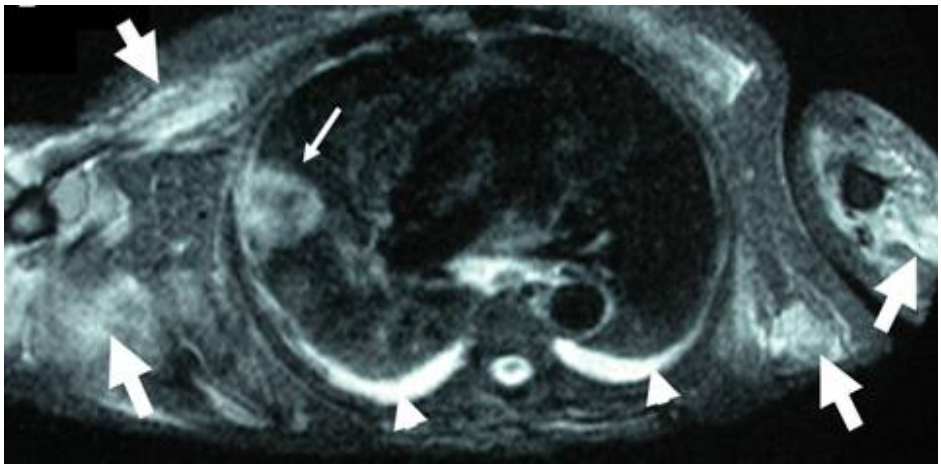

Fig. (42): A 64-year-old man was referred for assessment of a symmetric violaceous rash of the dorsal aspect of the fingers, trunk, olecranon processes and malleoli. An oedematous, blue-purple discolouration of the eyelids was also apparent. The patient complained of severe weakness of the proximal muscles and dysphagia. T2-weighted magnetic resonance imaging showed marked swelling and diffuse dyshomogeneity of skeletal muscles (thick arrows), a 4 cm peripheral mass in the upper lobe of the right lung (thin arrow) that was histologically identified as squamous cell carcinoma and staged as T3 N0 M0. and bilateral pleural effusion (arrowheads) ***(Daniele et al., 2007).***

MRI is useful in differentiating steroid myopathy from continued inflammation.Also,it may serve as a guide in selecting a muscle biopsy site. Chest radiography should be obtained at the time of diagnosis and when symptoms develop. A barium swallow allows evaluation of esophageal dysmotility. US of the muscles has been suggested for evaluation but has not been widely accepted. CT scanning is useful in the evaluation of potential malignancy that might be associated with inflammatory myopathy ***(Jeffrey and Callen, 2009).***

Inclusion body myositis (IBM):

IBM is characterized clinically by the insidious onset of slowly progressive proximal and distal weakness, which generally develops after the age of 50 years ***(Anthony and James, 2008).***

MRI showed marked muscle wasting and fatty infiltration. The quadricipital group of thighs was predominantly affected as compared with the flexor compartment (fig 43).

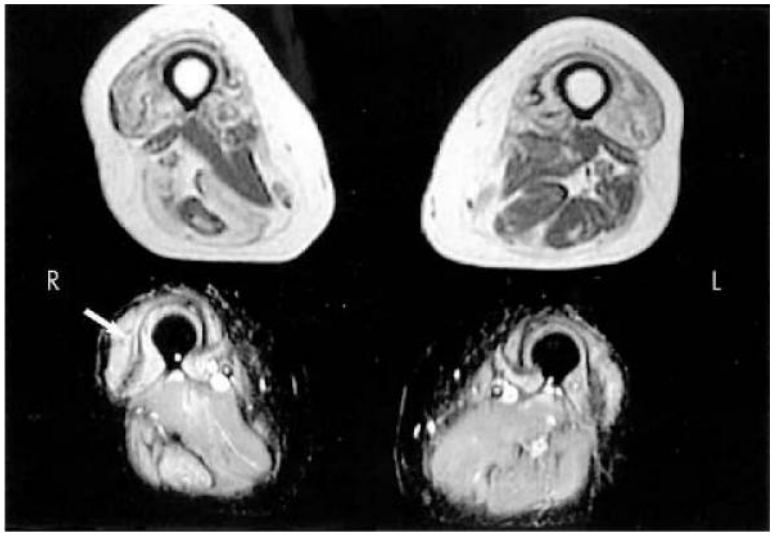

Fig. (43): Axial spin echo T1 and STIR images through the mid-portion of the two thighs. Spin echo T1 image (upper) shows fatty infiltration (high signal intensity areas) predominant in both quadricipital groups and in the posterior group of the right thigh. STIR image (lower) demonstrates oedema mostly in the quadricipital group (arrow) ***(Ranque et al., 2005).***

Congenital Myopathies

The term "congenital myopathy" was originally used to describe a group of myopathic disorders presenting preferentially, but not exclusively, at birth. Usually the congenital myopathies present in infancy as generalized hypotonia and weakness. Motor milestones are typically delayed. Affected infants are usually hypotonic and display delayed motor development. Some congenital myopathies can present later in childhood or even in early adulthood. The congenital myopathies were initially considered as nonprogressive, although it is now clear that progressive weakness can occur. Congenital myopathies can be inherited in an autosomal-dominant, autosomal-recessive, or X-linked pattern. Within families, there can be considerable variation with respect to disease presentation and degree of muscle involvement. The serum creatine kinase (CK) levels are either normal or only mildly elevated ***(Anthony and James, 2008).***

Interpretation of the muscle biopsy is critical in establishing the diagnosis. Each condition has significant clinical heterogeneity. There are few well-documented reports of MRI findings in congenital myopathies ***(Ikeda et al., 2002).***

CCD:

Patients with CCD show a consistent pattern of selective muscle involvement in the thighs and lower legs featuring marked involvement of the vasti, sartorius, and adductor magnus, and relative sparing of the rectus femoris, adductor longus, and hamstring muscles. At calf level there is marked involvement of the soleus, the lateral head of the gastrocnemius, and the peroneal group, with relative sparing of other anterior compartment muscles and the medial head of the gastrocnemius. These patterns can be observed in all cases with or without a confirmed ryanodine receptor 1 (RYR1) mutation ***(Eugenio et al., 2007).***

Nemaline Myopathy:

Patients with nemaline myopathy have highly heterogeneous findings on muscle MRI corresponding to the wide range of clinical phenotypes and genes that have been reported. A distinct pattern can be identified in patients with the form of nemaline myopathy secondary to mutations in the Nebulin gene (NEB), who often have little or no involvement of the thigh muscles, with selective involvement of the rectus femoris. At calf level there is early involvement of the tibialis anterior, and the pattern of selective involvement within the anterior compartment is inverse to the one seen in CCD, in which the peroneal group is typically affected and the tibialis anterior is usually spared.(fig 44) ***(Jungbluth et al., 2004).***



(A)



(B)

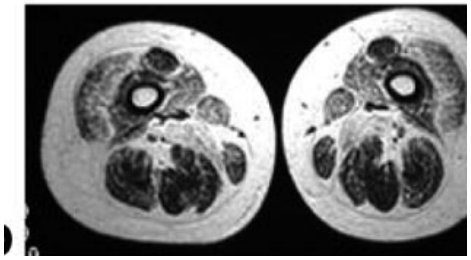

(C)

Fig. (44): T1W MRI, transverse sections of the proximal thigh in three patients with congenital myopathies secondary to mutations in the *RYR1* gene. Note the marked increase in abnormal signal within the vasti, sartorius, and adductor magnus, and relative sparing of the rectus femoris, adductor longus, gracilis, and semitendinosus (**a** and **b**), which is more obvious in the patient with more severe weakness (**c**) ***(Eugenio et al., 2007).***

Centronuclear (myotubular) myopathy:

Centronuclear myopathy is an inherited neuromuscular disorder defined by a) numerous centrally placed nuclei on muscle biopsy and b) clinical features of a congenital myopathy ***(Heinz et al., 2008).***

Muscle MRI in cases of centronuclear myopathy secondary to mutations in the *DNM2* gene show a characteristic progressive sequence (Fig.45) with early involvement of the ankle plantarflexors and subsequent signal changes within the hamstring muscles and, finally, the anterior thigh ***(Schessl et al., 2007).***

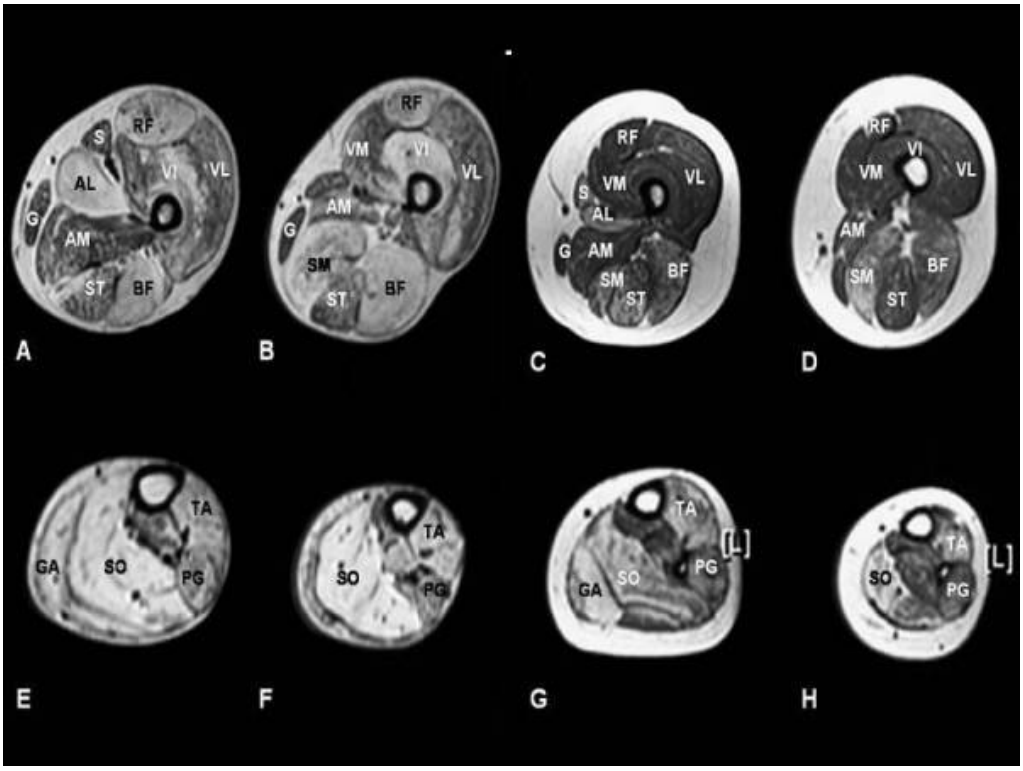

Fig. (45): Selective muscle involvement in a 59-year-old man (A, B, E, F) and his 28-year-old daughter with centronuclear myopathy (C, D, G, H) due to a mutation in the dynamin 2 *(DNM2)* gene, muscle MRI, transverse, T1-weighted sections from the proximal (A, C) and distal (B, D) thigh and the proximal (E, G) and distal lower leg (F, H).
In the thigh there is increased signal intensity within the adductor longus (AL), semimembranosus (SM), rectus femoris (RF), biceps femoris (BF), and vastus intermedius (VI) muscles with relative sparing of the adductor magnus (AM), gracilis (G), sartorius (S), semitendinosus (ST), vastus lateralis (VL), and vastus medialis (VM) muscles. Within the lower leg, there is predominant involvement of the gastrocnemius (GA), soleus (SO) an tibialis anterior (TA) muscles with relative sparing of the peroneal group (PG). Muscle involvement, particularly within the thigh, is milder in the daughter compared to her father. The pattern is distinct from that reported in congenital myopathies associated with mutations in the skeletal muscle ryanodine *(RYR1)* gene ***(Carsten and Joachim, 2007).***

MmD:

Multi-minicore Disease (MmD) is an inherited neuromuscular disorder defined by a) multiple areas with reduced oxidative activity running along an only limited extent of the longitudinal axis of the muscle fibre ("minicores") and b) clinical features of a congenital myopathy.

The pattern of selective involvement on muscle imaging is similar to that observed in classic CCD caused by dominant *RYR1* mutations (fig 46) ***(Heinz, 2007).***

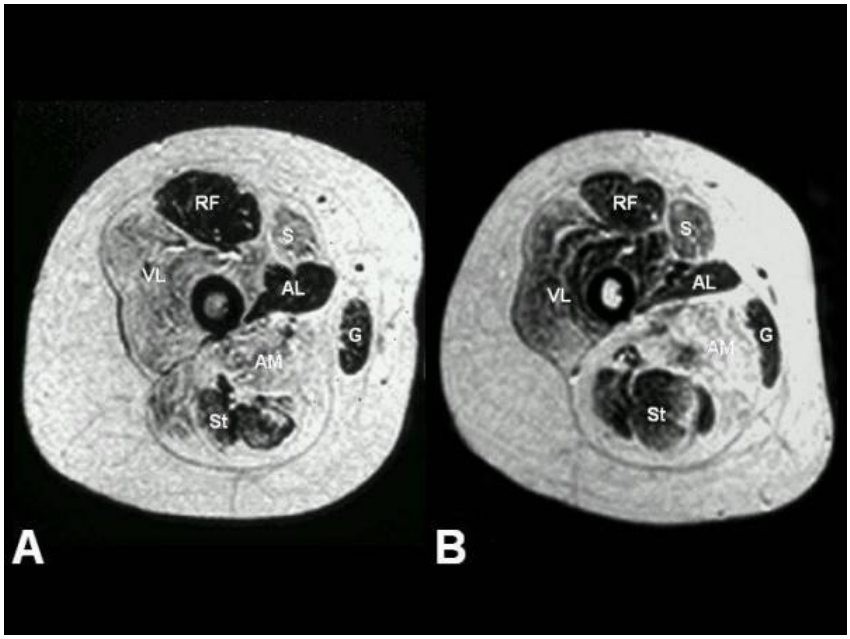

Fig. (46): Selective muscle involvement in *RYR1*-related central core disease (CCD) and multi-minicore disease (MmD). Muscle MRI of the thigh, T1-weighted images. A) A transverse section from the proximal thigh in a 12-year-old patient with central core disease (CCD) due to a dominant mutation in the skeletal muscle ryanodine receptor *(RYR1)* gene. There is a distinct pattern of selective involvement characterized by marked increase in signal within the vasti, sartorius (S), and adductor magnus (AM), and relative sparing of the rectus femoris (RF), adductor longus (AL), gracilis (G), and hamstring muscles. B) A transverse section from the proximal thigh in a 17-year-old girl with Multi-minicore disease due to a homozygous recessive *RYR1* mutation demonstrating a comparable pattern of selective involvement ***(Jungbluth et al., 2004).***

Myopathies with tubular aggregates:

Tubular aggregates are a distinctive morphological finding seen in a wide variety of different muscular disorders. However, they present a major abnormality in certain disorders, of which the most important is myopathy, The T1-weighted images showed normal intramuscular signal intensity. Muscle

MRI evaluated on T2-weighted STIR sequences showed intense signal in the medial part of the gastrocnemius muscles, much more in the left one, indicating edema (Fig. 47) ***(Mahjneha et al., 2007).***

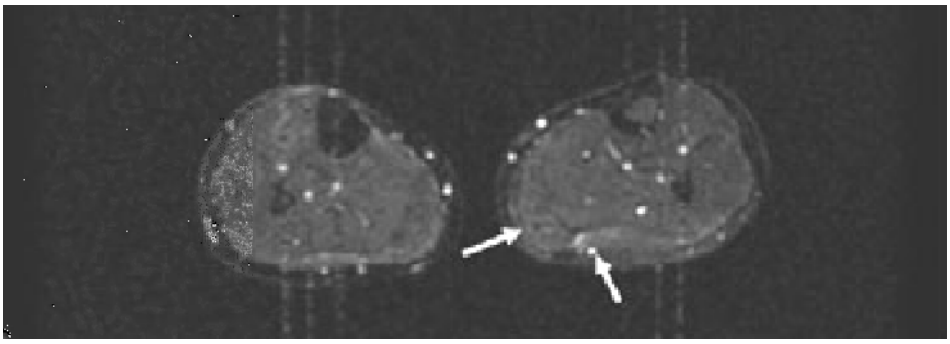

Fig. (47): Muscle MRI evaluated on STIR sequences showed intense signal in the medial part of the gastrocnemius muscles indicating edema (arrow) ***(Mahjneha et al., 2007).***

Reducing body myopathy:

Reducing body myopathy is a rare pathologically defined myopathy causing progressive weakness and characteristic intracytoplasmatic myofiber inclusions. Muscle MRI findings showed a distinctive pattern of muscle alteration, with a predominant involvement of postero-medial muscle at thigh level and of soleus at calf level, with a striking sparing of glutei muscles that also appeared to be hypertrophic (fig 48). These findings may help in the differential diagnosis of these disorders ***(Astrea et al., 2009).***

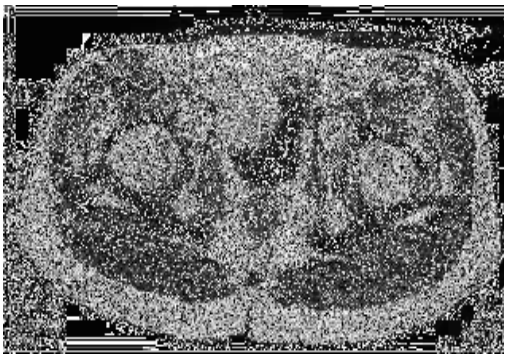

(A)

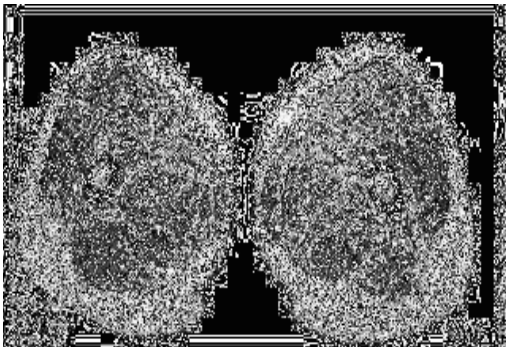

(B)



(C)

Fig. (48): Muscle MRI. T1 weighted transverse scans performed through pelvis, thigh and calf. showed relative sparing of the glutei **(A)** and a predominant involvement of adductor magnus and posterior muscles at thigh level **(B)** Note the progressive involvement of distal muscles **(C)** ***(Astrea et al., 2009).***

Neuroimaging of Peripheral Nerve Diseases

Medical imaging is playing an increasingly important role in the diagnosis of disorders affecting the peripheral nerves and muscles ***(Aaron et al., 2004).***

Plain radiographs are useful as a screening tool for suspected aneurysms, malignant disease **or** presence of a cervical rib ***(Jeffrey et al., 2008).***

High-frequency US of peripheral nerve and muscle is a relatively inexpensive and accessible diagnostic method to provide further information in the assessment of nerve injury. Although the resolution of ultrasound imaging is below that of MRI, this test can be performed in the office setting, has the advantage of real-time imaging, and is of particular use in patients who cannot tolerate MRI. US enables more dynamic observation of in vivo nerve segments (e.g., retroepicondylar subluxation of the ulnar nerve) and focal structural changes that accompany nerve injury (e.g., swelling, nerve continuity, neuroma formation**).** In neurogenic tumers, it can often demonstrate the associated nerve entering or leaving the lesion ***(Jeffrey et al., 2008).***

CT can be useful in determining the presence of a structural mass in the pelvic region. Both computed tomographic scanning and magnetic resonance imaging have

been used to evaluate the lumbosacral plexus ***(Moore et al., 2001).***

In the past, the practical application of MR imaging of nerves has been limited by technical difficulties in obtaining good image contrast to help distinguish nerve from neighboring tissues.

Recently, however, advances and enhancements of MR imaging techniques have transformed the evaluation of a variety of conditions that have posed diagnostic challenges in the past ***(Aaron et al., 2004).***

The term MR neurography is used to describe the new techniques for nerve imaging that greatly improve the reliability of identification of peripheral nerves in images and often make it possible to generate tissue specific images of nerves analogous to angiograms. These images enable the physician to examine the peripheral nerve for anatomic abnormalities ***(Aaron et al., 2004).***

The brachial and lumbosacral plexus are formed by multiple ventral rami of spinal nerves. The C5 through T1 spinal nerves form the brachial plexus as roots that subsequently form the trunks, divisions, cords, and branches. The lumbosacral plexus is composed of two separate plexus. The lumbar plexus is formed by L1 through L3 spinal nerves and the sacral plexus from L4 through S4 spinal nerves. Both

the lumbar and sacral plexus divide into anterior and posterior branches. The posterior branches of the lumbar plexus are located within the psoas muscle and the sacral plexus is anterior to the piriformis muscle. The sciatic nerve is formed by the tibial portion from the anterior branch of the sacral plexus and the peroneal portion from the posterior branch. The sciatic nerve courses through the greater sciatic foramen of the pelvis accompanied by the piriformis muscle and gluteal vessels and nerves. The sciatic nerve divides into tibial and peroneal nerves in the lower thigh region ***(Maravilla et al., 1998).***

The intrinsic contrast properties of adipose tissue and both endoneurial and axoplasmic fluid allow distinct MR imaging of peripheral nerves. The individual fascicles of larger nerves are visualized as smooth, uniform, soft tissue structures isointense to muscle on T1-weighted MR images and are well delineated by interspersed epineural adipose tissue. Fascicles appear as high signal intensity dot-like structures on T2-weighted images that generally show less intense signal than adjacent blood vessels and mild to moderate hyperintense signal compared to adjacent muscle. The nerve fascicles are separated by low-signal intensity on T2-weighted images because of interspersed connective tissue and fat-suppressed adipose tissue ***(Moore et al., 2001).***

Typical MR peripheral nerve imaging protocols use high-resolution spin-echo T1-weighted images to show anatomic detail and fat-suppressed T2-weighted or STIR images to detect abnormal nerve signal intensity (Figs. 49,50). STIR images are preferable to provide uniform and consistent fat suppression with excellent T2 contrast. STIR imaging however, has a low SNR and is sensitive to blood-flow artifacts. Flow saturation pulses are useful to attenuate these phase-shift artifacts. Gadolinium enhanced fat-suppressed T1-weighted images are typically reserved for patients with neoplasm, suspected infection, and post-surgical evaluation ***(Maravilla et al., 1998).***

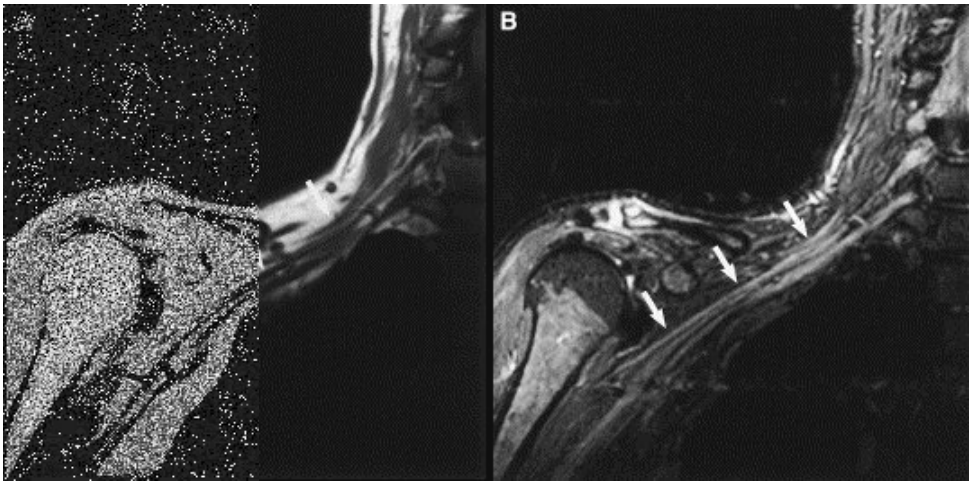

Fig. (49): Normal brachial plexus. **(A)** Oblique coronal T1-weighted image (to maximize long axis of brachial plexus) of the lower brachial plexus shows the brachial plexus isointense to muscle extending from the trunks to cords (white arrows) as well as the proximal roots of C8 and T1. **(B)** Oblique coronal STIR images (same plane as A) show the normal brachial plexus (white arrows) with signal higher than muscle but less than vascular structures in the neck ***(Maravilla et al., 1998).***

Fig. (50): Normal sciatic nerve. **(A)** Coronal T1-weighted image oriented to long axis of sciatic nerve as it courses through the greater sciatic foramen (arrows). Nerve fascicles are isointense to muscle and surrounded by high signal of adipose tissue within the epineural space. **(B)** Coronal T2-weighted FSE image with fat saturation obtained in same plane as shown in A. Fascicles appear bright in signal intensity but remain less intense than adjacent blood vessels ***(Maravilla et al., 1998).***

A major disadvantage of these conventional imaging techniques, however, is their inability to produce three-dimensional images, such as maximum intensity projection (MIP) images that depict the entire length of the nerve sheaths, because of the high signal of the surrounding background tissue. Furthermore, vascular structures, such as veins adjacent to nerves, are difficult to distinguish from the nerves of the brachial plexus because of their similar signal intensity on T2- and T1-weighted MR images. Consequently, image interpretation can be time consuming, and precise lesion localization can be difficult ***(Freund et al., 2007).***

The addition of a diffusion-weighted (DW) MR sequence to a conventional MR imaging protocol used to assess the brachial plexus may enable us to overcome some of the

disadvantages discussed above. DW MR neurography may provide improved contrast between the nerves of the brachial plexus and the surrounding tissues. Theoretically, this could facilitate imaging of the long trajectory of the brachial plexus. Compared with the combination of axial, coronal, and sagittal views obtained with conventional MR sequences, the high contrast of DW MR neurography may enable a more straightforward three-dimensional MIP evaluation of the brachial plexus ***(Jeroen et al., 2008).***

Clinical Examples of DW MR Neurography:

In three patients with schwannoma, the relationship between the tumor and its original nerve root was seen (Fig 51) .In one patient with a dumbbell-shaped schwannoma, the typical shape of the schwannoma was well depicted on a DW MR neurographic image ***(Jeroen et al., 2008).***

.



Fig. (51): MR images in three patients with pathologically proved schwannoma. *A–D* were obtained in patient 1, a 32-year-old man; *E* and *F* were obtained in patient 2, a 67-year-old woman; and *G* and *H* were obtained in patient 3, a 35-year-old woman. *A,* Coronal T1-weighted image shows a fusiform-shaped mass in the right supraclavicular region (arrowhead). *B,* DW MR neurographic image shows that the tumor originates from the nerve root at the right side of the C6 nerve. *C, D,* Axial source images show multiple peripheral nerve roots and the connection between the tumor *(T)* and the right-sided C6 nerve. The C7 and C8 nerves are also visible. *E,* Axial T2-weighted image shows a high-signal-intensity mass (arrowhead) in the left supraclavicular region with the typical shape of a neurogenic tumor. *F,* DW MR neurographic image shows that the tumor originates from the left C7 nerve root. *G,* T1-weighted axial image obtained after contrast material administration shows a dumbbell-shaped mass (arrowheads) in the left neural foramen at the level of the C6 nerve. *H,* DW MR neurographic image also shows a dumbbell-shaped mass at the level of the C6 nerve ***(Taro et al., 2008).***

Higher-tesla MRI scanners (3.0 T) offer enhanced resolution that may provide images with imaging quality equal to or greater than that of MR neurography. Another emerging technique, diffusion tensor imaging (DTI) and tractography of peripheral nerves (also performed on 3.0 T MRI), is based on the principle that water molecules have anisotropic diffusion properties (or a preferred orientation) in white matter fiber tracts, compared with isotropic diffusion (equal in all directions) in surrounding tissues (Fig. 52). Despite their promise, the routine use of 3.0 T imaging and DTI is limited by their availability ***(Jeffrey et al., 2008).***

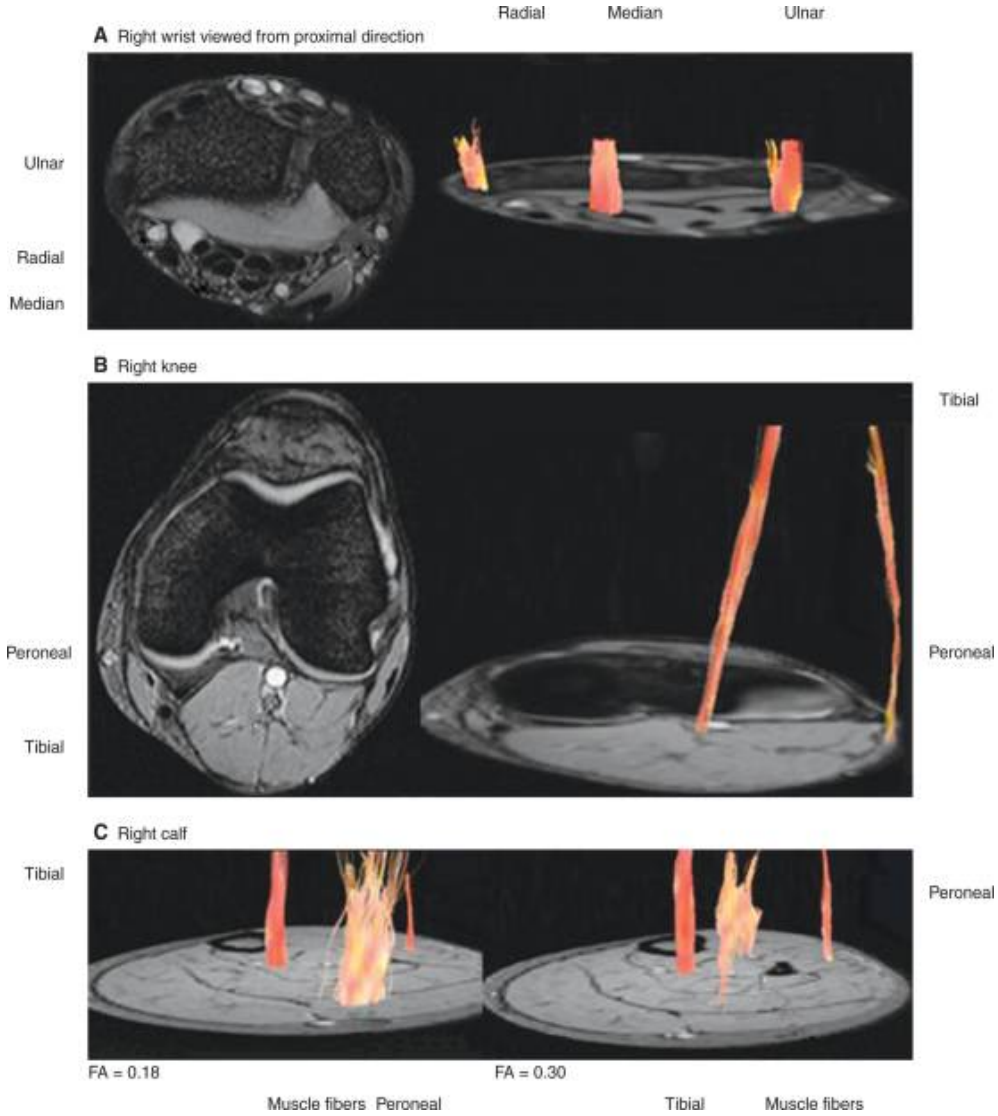

Fig. (52): Magnetic resonance tractography. Peripheral nerves of the right wrist, knee, and calf imaged with diffusion tensor imaging and compared to their corresponding MRI anatomy. **(A),** Median, ulnar, and radial nerve of wrist. (**B),** Posterior view of tibial and peroneal nerve at the knee. **(C),** Tibial and peroneal nerve at the mid-calf level ***(Hiltunen et al., 2005).***

Recently, the 3D STIR SPACE sequence is mainly used to rapidly image the postganglionic nerve roots of the entire brachial plexus with a sufficiently high resolution in a variety of pathologic conditions. It is useful for the initial screening of patients with neoplastic conditions involving the brachial plexus and it is a valuable adjunct in the depiction of nerve site compressions ***(Vargasa et al., 2010).***

Selected clinical applications:

1. Tumors:

In tumoral pathology, MR imaging is used to assess whether a mass is intrinsic or extrinsic to the brachial plexus and to precisely determine the site of the displaced, compressed or destroyed nerve fibers. The information from MR imaging is also used in the preoperative planning procedure. In suspected brachial plexopathy caused by a tumor, 3D STIR SPACE sequence is routinely used now; it is a robust high-quality technique that allows studying the entire brachial plexus on both sides from the proximal region to the periphery in one acquisition (Fig. 53). It is a very useful technique for the characterization and detection of tumors involving the plexus in its postganglionic area ***(Vargasa et al., 2010).***

.

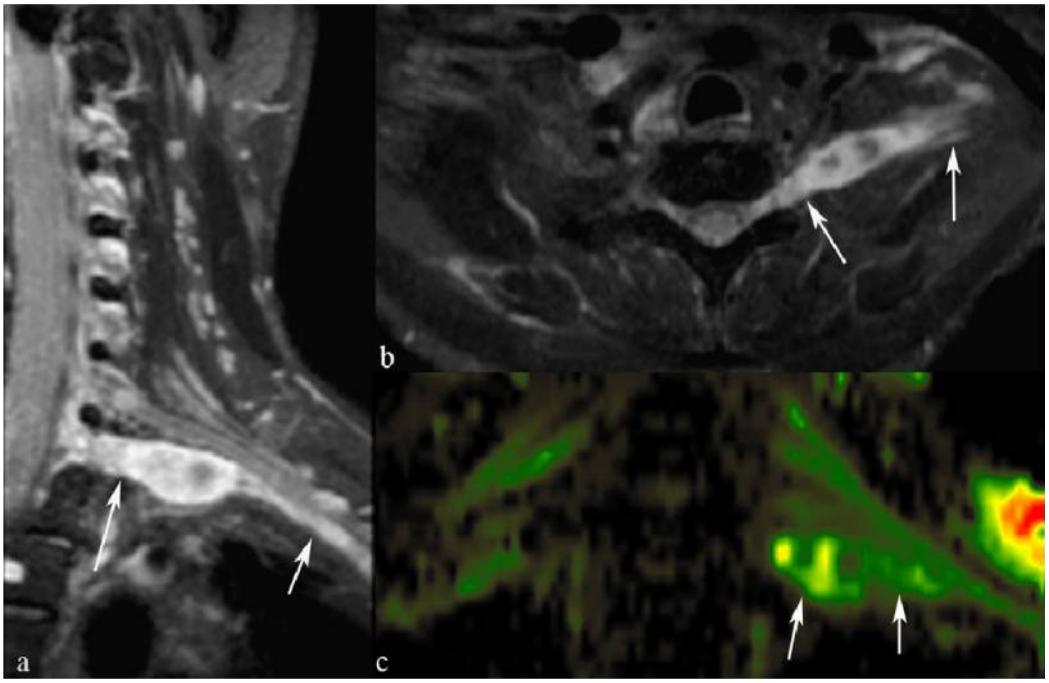

Fig. (53): 3D STIR SPACE coronal **(a),** axial **(b)** curved reconstructions and coronal color rendered DW neurography **(c)** nicely showing a schwannoma originating in the left C8 root (arrows on all images). Note that the entire tumor can be easily depicted on one image due to the curved reconstructions ***(Takahara et al., 2008).***

In malignant tumors the infiltration pattern, as well as the degree of perineural dissemination are well demonstrated and their response to treatment (Fig. 54) ***(Yoshikava et al., 2006).***

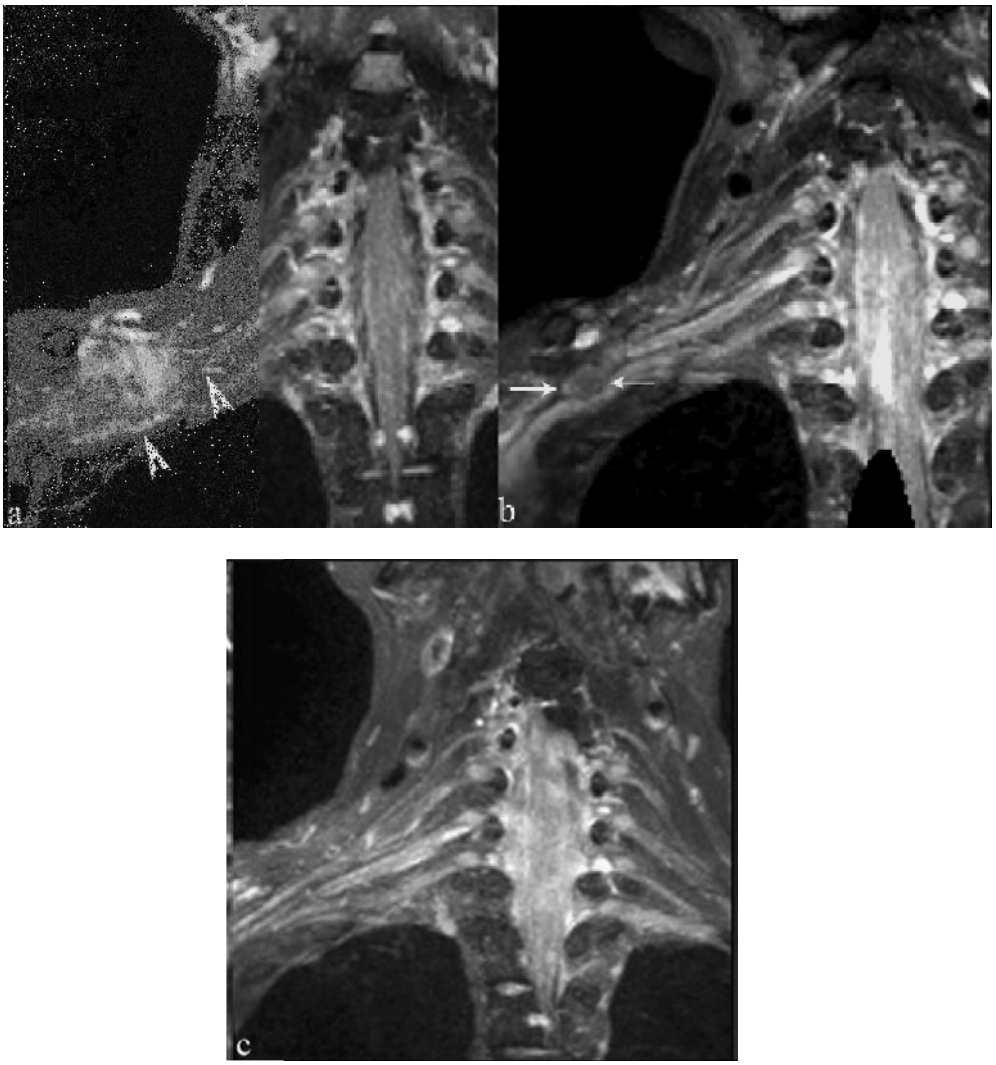

Fig. (54): STIR 3D coronal oblique MIP reconstructions obtained before treatment **(a),** 1 month after treatment **(b)** and at the end of treatment **(c).** **(a)** Lymphoma in the supraclavicular region before treatment (arrowheads). Note involvement of the C7 and T1 nerve roots and the moderately high signal of the lesion. **(b)** Size reduction 1 month after treatment (arrows). Note that the signal of the tumor mass diminishes. **(c)** Disappearance of the tumor at end of treatment ***(Yoshikava et al., 2006).***

2. Trauma:

Peripheral nerve injuries are divided into two basic groups based on the mechanism of injury: traumatic axonal disruption caused by a crush injury or transection and compressive neuropathy secondary to neoplasm, entrapment, or non-disruptive trauma (Fig. 55). Both mechanisms increase permeability of endothelial junctions of the endoneurium and allow an influx of free water into the endoneurial space. This may account for increased signal on T2-weighted or STIR images often approaching that of adjacent blood vessels. The nerve often becomes enlarged and fascicular architecture may be distorted ***(Maravilla et al., 1998).***

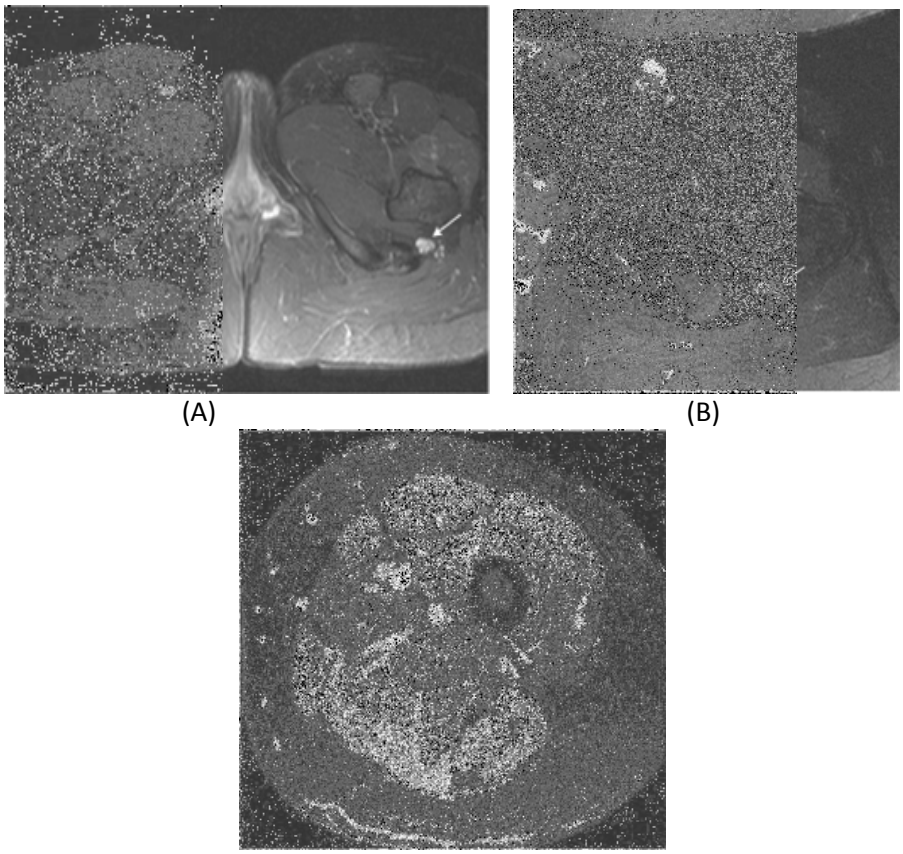

Fig. (55): Magnetic resonance neurography. These images were obtained in a 23-year-old woman 1 month after she was diagnosed with a compressive left sciatic neuropathy due to prolonged compression (alcohol-induced coma). A, Large field-of-view axial T-weighted image with fat suppression demonstrates marked T2 signal hyperintensity in the left sciatic nerve (solid arrow). The large field of view allows comparison with the normal right side, which can be useful in cases of subtle T2 signal hyperintensity to differentiate from normal nerve signal. B, Small field-of-view axial T2-weighted image with fat suppression demonstrates the same changes in the left sciatic nerve as in A (solid arrow), but with improved spatial resolution, allowing for detection of small mass lesions and subtle signal changes. C, Small field-of-view axial T1-weighted image obtained after injection of intravenous contrast demonstrates minimal nerve enhancement (solid arrow) and enhancement of the hamstring musculature (open arrow). Note that although most regions of T2 signal hyperintensity also enhance, the signal changes may be subtler than on T2-weighted images. Contrast-enhanced images are most useful for detecting small mass lesions and characterizing solid versus cystic lesions ***(Maravilla et al., 1998).***

In traumatic injury to the brachial plexus, MR imaging with conventional 2D sequences and with the 3D STIR SPACE sequence can reliably detect masses that compress or stretch the plexus such as post-traumatic hematomas, clavicular fractures, focal or diffuse fibrosis and post-traumatic neuromas. In addition, the 3D STIR SPACE sequence allows the visualization of postganglionic ruptures of nerve roots, cords and trunks of the brachial plexus but a 3D T2w high resolution MR myelography sequence should be used additionally when proximal preganglionic lesion is suspected (Fig. 56) ***(Vargasa et al., 2010).***

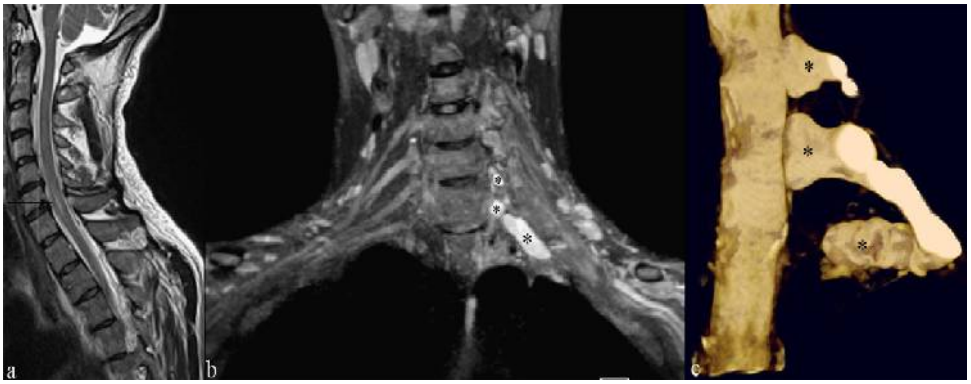

Fig. (56): (a) Sagittal T2w FSE image through the cervical spine shows a high signal intensity area in the spinal cord suggesting a post-traumatic lesion (black arrow). Coronal 3D STIR sequence **(b)** and 3D volume rendering of a 3D T2w MR myelography sequence **(c)** show a normal brachial plexus on the right side and multiple avulsions (asterisks) with the interruption of the nerve roots, cords and trunks on the left side ***(Vargasa et al., 2010).***

It is important to image the muscle groups supplied by the nerve of interest because secondary denervation changes may be seen. Early denervated muscle has normal size and

initially shows increased signal intensity on T2-weighted images. Chronic denervation leads to muscle atrophy and therefore decreased size and adipose tissue infiltration. This is best evaluated on T1-weighted images of the affected muscle groups ***(Maravilla et al., 1998).***

3. Entrapment syndromes:

Compressive neuropathy may be caused by intrinsic or extrinsic compression of a peripheral nerve. Extrinsic compression is seen in entrapment syndromes and occurs in locations where the nerve has an intimate association with bone, muscle, or vascular structures ***(Maravilla et al., 1998).***

- Entrapment Syndromes of the brachial plexus:

Detailed clinical, neurologic and electrodiagnostic examinations can determine the exact position of compression and entrapment of the brachial plexus, which is then confirmed by MRI. The brachial plexus can be compressed in three main areas along its course: (1) The interscalene triangle, (2) the first thoracic rib and the clavicle, and (3) the retropectoral minor space. These three locations are all classified as thoracic outlet syndromes (TOS), which may involve nerves, vessels or both. In suspected entrapment syndromes, the functional 3DSTIRMRwith postural maneuvers (upper limb raised) is done, which are helpful in analyzing dynamically induced compression patterns. The 3D STIR MR sequence is a good

supplementary tool for the assessment of nervous compression, especially in cases with positive clinical features of TOS but negative features of TOS at neutral MR imaging (Fig. 57) ***(Viallon et al., 2008).***

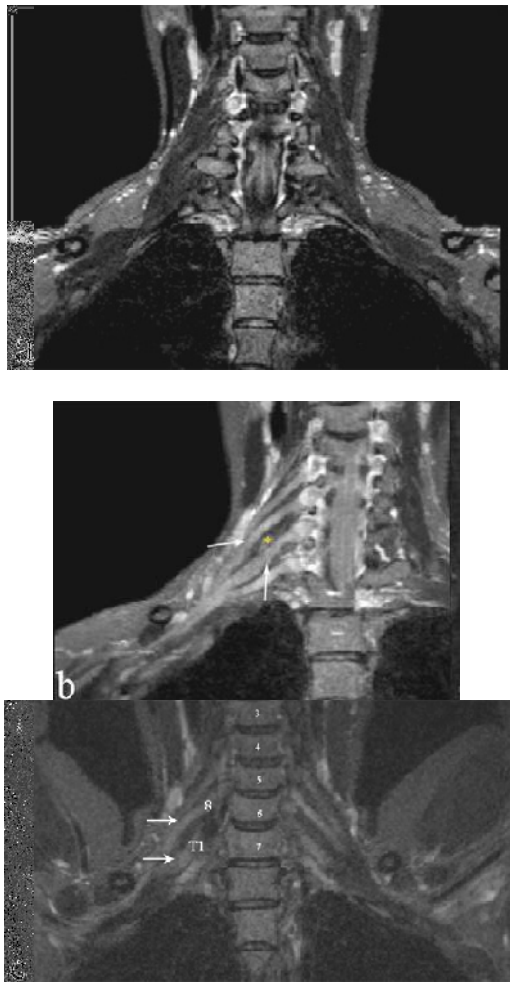

Fig. (57): (a) Coronal 3D STIR source image with upper limb along the body. **(b)** Coronal MIP reconstruction with upper limb along the body. **(c)** Coronal 3D STIR source image with upper limb raised. A conflict between the elongated C7 transverse process (asterisk) and the deformed nerve roots C8–T1 (arrows) is better appreciated in the position with the arms up than in the position with the arms along the body ***(Vargasa et al., 2010).***

- Entrapment Syndromes of the Median Nerve:

Carpal Tunnel Syndrome:

Carpal tunnel syndrome is the most common peripheral neuropathy of the upper extremity and results from compression of the median nerve beneath the transverse carpal ligament. The potential causes of compression include various congenital, inflammatory, infectious, idiopathic, and metabolic or endocrine processes and conditions (e.g., diabetes, pregnancy, and hypothyroidism) as well as trauma (Fig 58) and mass lesions (e.g., ganglion, lipoma, neurofibroma, fibrolipomatous hamartoma) (Fig 59). Repetitive use also may contribute to the development of carpal tunnel syndrome ***(Gustav et al., 2006).***

Carpal tunnel syndrome can be diagnosed with clinical examination and confirmed by nerve conduction studies .MRI is reserved for patients with atypical clinical presentation and inconclusive electrophysiologic tests. MRI findings of carpal tunnel syndrome, regardless of the underlying etiology, are diffuse or segmental enlargement of the median nerve, increased signal intensity of the median nerve on T2-weighted images, bowing of the flexor retinaculum, and flattening of the

nerve. MRI also may be helpful in evaluating patients with recurrent or persistent symptoms after surgical division of the flexor retinaculum by showing incomplete release of the flexor retinaculum, postsurgical fibrosis around the median nerve, or a mass lesion within the carpal tunnel and in those suspected of having rare entrapments. For example, MRI is especially helpful in identifying a mass lesion in patients with a lesion compressing the suprascapular nerve, ulnar nerve at the wrist or the posterior interosseous nerve ***(Amgad et al., 2009).***

(a)

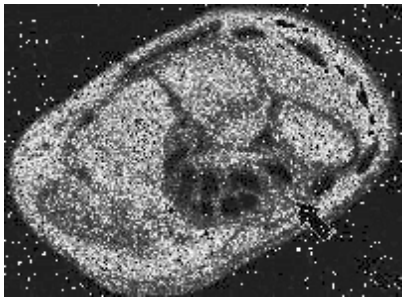

(b)

(c)

Fig. (58): Carpal tunnel syndrome in a 14-year-old female patient with a wrist trauma–related fracture of the capitate bone. Electrodiagnostic testing revealed a complete conduction block of the median nerve at the level of the carpal tunnel. **(a)** Coronal T2-weighted fat-suppressed fast SE MR image of the wrist shows a fracture of the capitate bone (arrow) without dislocation. **(b)** Axial T1-weighted SE MR image at the level of the carpal tunnel depicts moderate bowing of the flexor retinaculum (small arrows) and normal size of the median nerve (large arrow). **(c)** Axial T2-weighted fast SE MR image at the same level as **b** depicts increased signal intensity of the median nerve (arrow), a finding consistent with carpal tunnel syndrome ***(Gustav et al., 2006).***

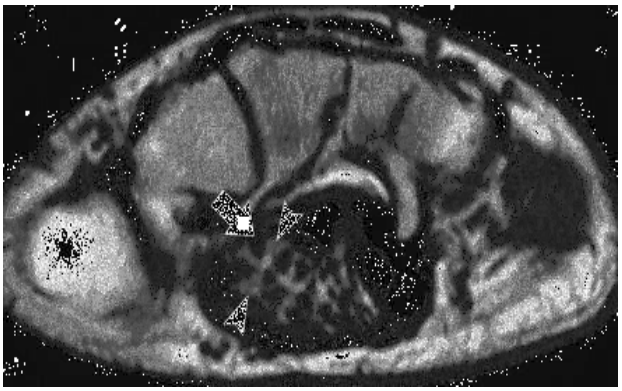

(a)



(b)

Fig. (59): Carpal tunnel syndrome in a 54-year-old man with a fibrolipomatous hamartoma of the median nerve. **(a)** Axial T1-weighted SE MR image at the level of the hook of the hamate shows enlargement of the median nerve, with hypointense nerve fascicles (arrow) surrounded by fibroadipose tissue (arrowheads). **(b)** Coronal contrast-enhanced T1-weighted fat-suppressed SE MR image depicts entrapment of the median nerve within the carpal tunnel (arrows) ***(Gustav et al., 2006).***

The sciatic nerve is compressed at the greater sciatic foramen by the piriformis muscle and the lateral femoral cutaneous nerve at the attachment of the inguinal ligament to the anterior superior iliac spine***(Moore et al., 2001).***

- Piriformis syndrome:

Imaging is increasingly capable of helping provide a reliable for diagnosis of piriformis syndromes; in some patients with severe symptoms, hyperintensity or shape changes are seen (Fig.60). When MR neurography can identify specific focal entrapments, open MR imaging can guide surgical procedures with limited surgical exposure to approach the site of the abnormality for decompression or release of adhesions ***(Moore et al., 2001).***

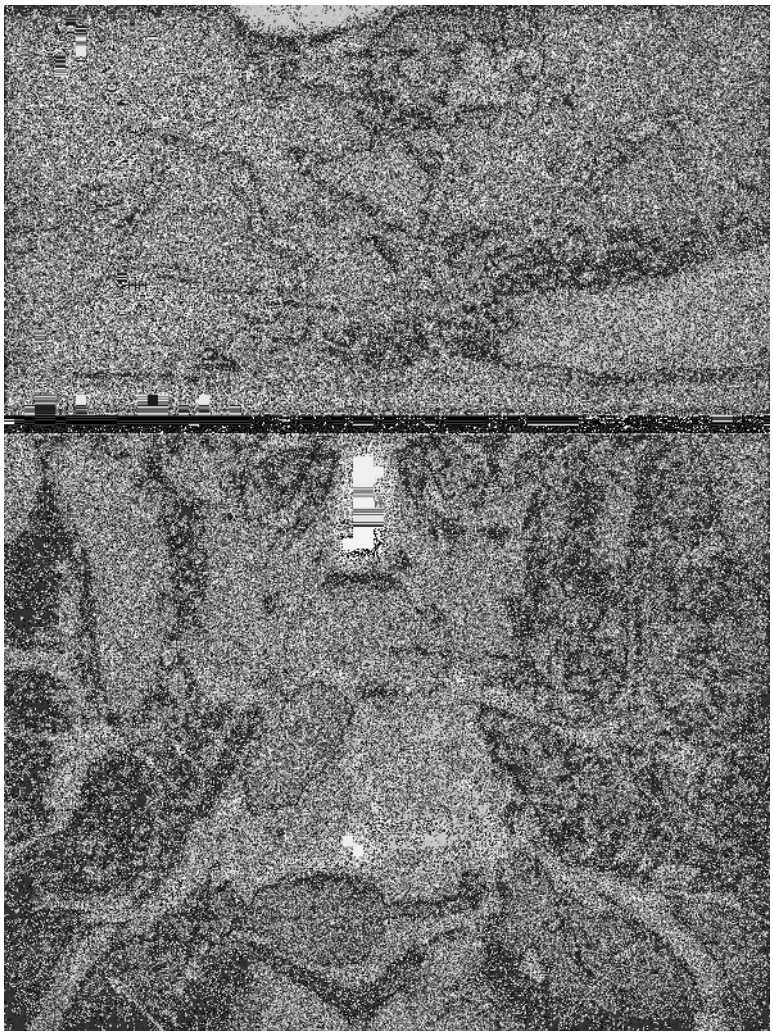

Fig. (60): Sciatic nerve hyperintensity in patients with piriformis syndrome. A variety of muscle and nerve abnormalities can be observed in the pelvis in patients with sciatica of nonspinal origin. In some cases, nerve fascicle swelling and hyperintensity can be observed. **(A)** Axial view just below the exit from the sciatic notch where the sciatic nerves (arrows) lie over the surface of the ischium with the piriformis muscle immediately posterior. **(B)** Coronal view demonstrating a linear fascicle pattern in the right sciatic nerve (right arrow) with hyperintensity and loss of fascicle pattern in the left sciatic nerve (left arrow). These arrows indicate the curve of the sciatic nerve as it turns downwards after exiting the sciatic notch. The three arrows on the right indicate the attachment of the piriformis muscle on the sacrum and across the sacroiliac joint. The three arrows on the left indicate the inferior surface of the piriformis muscle where the sciatic nerve and some gluteal vessels emerge from underneath it ***(Moore et al., 2001).***

4- Post-radiotherapy evaluation:

MRI is a valuable tool for the evaluation of patients who have undergone radiation therapy of the brachial plexus region. The characteristic imaging findings on MRI include uniform, symmetric thickening and enhancement of fibers and trunks and T2 hyperintensity of the plexus within the radiation portal, whereas a focal or diffuse, non-uniform, asymmetric enhancing mass suggests recurrent disease. On the 3D STIR SPACE sequence and on the fat saturated T1w sequence after Iv gadolinium, diffuse T2 hyperintensity and contrast enhancement of the plexus and of the surrounding tissues may be seen for months to years after treatment and differentiation from recurrent disease may not be possible on a single MR examination necessitating follow-up exams ***(Vargasa et al., 2010).***

Inflammatory neuropathies:

GBS:

Spine MRI findings: Nearly 2 weeks after presentation of symptoms, lumbosacral MRI can show enhancement of the nerve roots with gadolinium caused by disruption of the blood-nerve barrier. This imaging study has been described to be 83% sensitive for acute GBS and present in 95% of typical cases ***(Brian et al., 2009) and (Tarakad et al., 2009).***

Selective anterior nerve root enhancement appears to be strongly suggestive of GBS. The cauda equine nerve roots are enhanced in 83% of patients ***(*Andrew *et al., 2010) and (Cynthia et al., 2009).***

CIDP:

Imaging studies can provide supportive evidence of CIDP. MRI of the spine with gadolinium enhancement may show enhancement of nerve roots (fig.61) ***(Richard, 2010).***

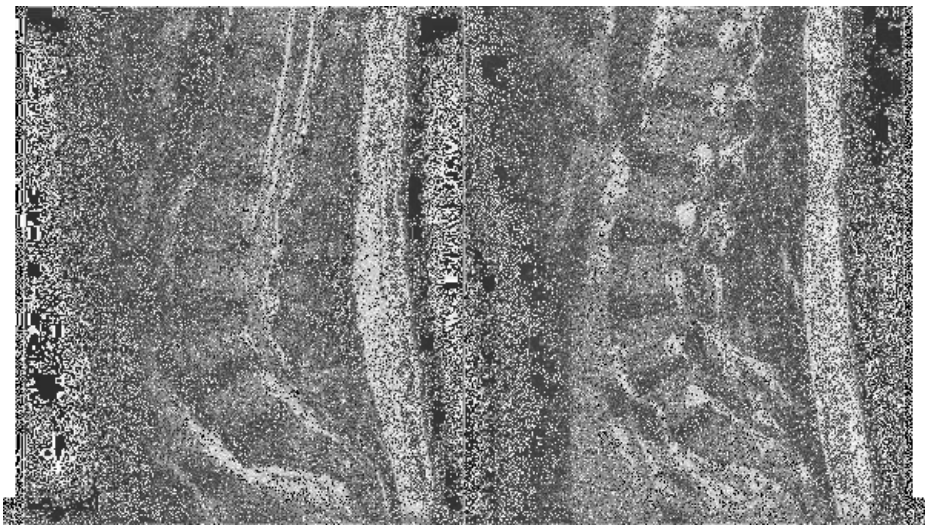

Figure (61): T2-weighted postgadolinium sagittal lumbar MR image: Diffuse enlargement of the cauda equina with abnormal enhancement in patient with CIDP (**A**). The hypertrophic nerve roots are best appreciated in parasagittal images (**B**) ***(Jeffrey et al., 2008).***

Root hypertrophy can be shown by MRI at the lumbar or cervical level in patients with CIDP and can occasionally cause clinical findings that are attributable to lumbar or cervical stenosis. Because inflammation can be widespread along nerves in CIDP, contrast enhancement and hypertrophy are sometimes

shown by conventional MRI at the plexus level. Besides conventional MRI sequences, diffusion neurography, which is a modified diffusion-weighted MRI technique, might be a promising method to identify abnormalities in nerves of patients with CIDP ***(Jean et al., 2010).***

Inherited neuropathies:

MRI can demonstrate enlarged nerves, not only at the level of the spinal roots but also in the limbs, which may help in distinguishing hereditary from acquired demyelinating neuropathy. Sonography of peripheral nerves can play a similar role ***(Timothy and Thomas, 2009).*** More recent studies have documented involvement of the foot muscles early in the disease course, with subsequent variable involvement of the proximal leg musculature. Subclinical central nervous system disease has been described in several subtypes of CMT. These forms are associated with abnormalities on brain MRI. MRI of the muscles may also help in the differentiation between CMT1A and CMT2A. CMT1A patients have more significant involvement of peroneal nerve innervated muscles while fatty infiltration involving superficial posterior compartment muscles is more common in CMT2A ***(Francisco et al., 2009).***

High-resolution ultrasonography of the median nerve and other peripheral nerves may serve as an adjunct to electrodiagnosis in Charcot-Marie-Tooth disease type 1A ***(Divakara, 2009).***

Infectious neuropathies:

Leprous neuropathy:

Magnetic resonance (MR) neurography in special situations

- MR neurography can be performed by using custom-made, high-resolution phased-array coils and a variety of fat-saturation sequences to study gross nerve morphology and internal fascicular architecture. This technique has been used to assess the presence of neuropathy, including active reversal reactions.
- Tuberculoid leprosy results in nerve thickening and abscesses that may be detected as thickened nerves with increased signal intensity on T2-weighted images.
- Nerve entrapment in osseofibrous tunnels occur in leprosy. Compression of the nerve appears as flattening of the normal circular cross-sectional appearance of the nerve with increased signal intensity on T2-weighted images, and the presence and configuration of the osseofibrous tunnels may be apparent on MRI.
- Alteration in the fascicular architecture, increased signal intensity on T2-weighted images, and gadolinium enhancement are observed in nerves affected by acute reversal reactions. With treatment, normal T2 signal intensity and reduced enhancement have been reported ***(Sridharan and Lakshmi, 2010).***

US:

High-frequency linear ultrasonographic probes can be used to demonstrate thickening of nerves and presence of osseofibrous compression ***(Scollard et al., 2006).***

Discussion

Interest in muscle MRI has been largely stimulated in the last few years by the recognition of an increasing number of genetic defects in the field of inherited neuromuscular disorders. Muscle US and CT have been used to detect the presence of muscle involvement in patients affected by these disorders, but until recently the use of muscle MRI has been, with a few exceptions, limited to detecting inflammatory forms ***(Eugenio et al., 2007).***

Because of the lack of sensitivity and specificity, MRI is not helpful in diagnosing inflammatory myopathies; however, it can help in monitoring its progress, and it may be used to guide decisions regarding muscle biopsy. The diagnosis of polymyositis is established by using serum enzyme levels and EMG studies and confirmed by means of diagnostic muscle biopsy ***(Francisco and Thomas, 2010).***

Muscle biopsy is the criterion standard for ascertaining the diagnosis of IBM. However, CT or MRI imaging of muscles may be useful in helping diagnose difficult cases ***(Helen et al., 2010).***

CK determination is the most specific test for muscular dystrophy. All muscular dystrophies result in some CK elevation during the active phase of the disease. The CK level is highest in DMD, with less elevation noted in BMD. US is a

relatively noninvasive technique that is used for screening patients with muscular dystrophy; this modality is rapidly replacing EMG in centers that have appropriately trained staff.Even in early stages of muscular dystrophy, US shows increased echogenicity in the affected muscles, with a corresponding reduction in the underlying bone echo.US has the advantage of noninvasiveness, and it is reliable for continued monitoring of the disease course over time ***(Twee, 2009).***

CT has also been extensively used to distinguish patterns of selective muscle involvement in muscular dystrophies. MRI techniques have shown that MRI has a higher sensitivity than CT for identifying early fatty replacement in muscles, and provides better anatomical details ***(Ozsarlak et al., 2001).***

Until the advent of molecular biology techniques, muscle biopsy was the definitive test for diagnosing and confirming muscular disease.Histologic changes depend on the stage of disease and the muscle selected.The optimal site for biopsy is the vastus lateralis muscle via a small lateral thigh incision. EMG finding is common with all myopathic processes and does not specifically identify muscular dystrophies ***(Twee, 2009).***

Congenital myopathies are distinguished from dystrophies in three respects: (1) characteristic morphologic alterations are demonstrated on biopsy, (2) they are manifested at birth as hypotonia and subsequent delayed motor development, and

(3) most are relatively nonprogressive and more benign than the muscular dystrophies. However, there are exceptions to all three generalizations. Onset can occur later in childhood and even in early adulthood, and some congenital myopathies have a severe course and fatal outcome. Moreover, the molecular defect of some congenital myopathies can result in the phenotype of a muscular dystrophy ***(Glenn, 2009).***

CK level is either in the reference range or mildly elevated in all of the congenital myopathies.It can be elevated moderately in CCD. Muscle biopsy shoud be obtained in all patients in whom a congenital myopathy is suspected. Pathological examination should be performed at a center whose staff has expertise in muscle pathology. Other causes of weakness need to be ruled out. In addition, the morphologic characteristics necessary to make the diagnosis need to be established. Ultrastructural examination of muscle is often necessary, since several of the pathologic features are based on the EM appearance of muscle ***(Glenn, 2009).***

Recent genetic advances suggest that the boundaries between conditions defined according to histopathological and clinical criteria are often indistinct and do not necessarily reflect different underlying molecular mechanisms.So, MRI is done as acomplementary tool in the diagnosis of congenital myopathies ***(Jungbluth et al., 2004).***

Nerve biopsies are generally less useful than muscle biopsies because the pathologic abnormalities are often nonspecific and frequently do not help distinguish one form of peripheral neuropathy from another ***(Hilton et al., 2007).***

Although rarely diagnostic of a specific entity, biopsy evaluation of peripheral nerve specimens plays a pivotal role in the workup of suspected neuropathy. Nerve biopsies are particularly helpful in diagnosing the following conditions: leprosy; amyloid neuropathy; leukodystrophies; sarcoidosis ***(Midroni and Bilbao, 1995).***

In leprosy, MR neurography can be performed by using custom-made, high-resolution phased-array coils and a variety of fat-saturation sequences to study gross nerve morphology and internal fascicular architecture. This technique has been used to assess the presence of neuropathy, including active reversal reactions. High-frequency linear ultrasonographic probes can be used to demonstrate thickening of nerves and presence of osseofibrous compression ***(Sridharan et al., 2010).***

In CIDP, EMG is a critical test to determine whether the disorder is truly a peripheral neuropathy and whether the neuropathy is demyelinating. However**,** imaging studies can provide supportive evidence of CIDP. MRI of the spine with gadolinium enhancement may show enhancement of nerve roots ***(Richard, 2010).***

Diagnosis of Guillain-Barré syndrome usually is made on clinical grounds. Laboratory studies are useful to rule out other diagnoses and to better assess functional status and prognosis. MRI is a sensitive but nonspecific test. Spinal nerve root enhancement with gadolinium is a nonspecific feature seen in inflammatory conditions and is caused by disruption of the blood-nerve barrier. Selective anterior nerve root enhancement appears to be strongly suggestive of GBS ***(Andrew et al., 2010).***

The diagnosis of most entrapment neuropathies can usually be established on clinical grounds alone. For typical cases of carpal tunnel and ulnar cubital syndromes, electrodiagnostic tests are not always necessary. Still, they provide useful information: confirming the clinical diagnosis .MRI and other imaging modalities are used for patients with atypical presentations of common disorders ***(Amgad et al., 2009).***

Evaluation of the brachial plexus is a clinical challenge. Physical examination has traditionally been a mainstay in evaluating and localizing pathology involving the brachial plexus. Electrophysiologic studies can be used to detect abnormalities in nerve conduction, but they are poor for localizing a lesion. EMG and MRI examinations are complementary ***(Sudhakar et al., 2009)***.

MRI sequences such as fat-saturated T2-weighted spin-echo, STIR, and gadolinium-enhanced T1-weighted spin-echo

sequences help in depicting subtle changes in the signal intensity of the nerves or enhancement and aid in refining the differential diagnosis. In addition, maximum intensity projections can make localization and visualization of the pathology most understandable for referring clinicians and surgeons ***(Sudhakar et al., 2009).***

So, imaging plays an essential role for the detection and analysis of pathologic conditions of the brachial plexus. Currently, several new techniques are used in addition to conventional 2D MR sequences to study the brachial plexus: the 3D STIR SPACE sequence, 3D heavily T2w MR myelography sequences, and the DW neurography sequence with fiber tracking reconstruction (tractography). The 3D STIR sequence offers complete anatomical coverage of the brachial plexus and the ability to slice through the volume helps to analyze fiber course modification and structure alteration. It allows precise assessment of distortion, compression and interruption of postganglionic nerve fibers thanks to the capability of performing MIP and multiplanar reconstructions (MPRs). The DW neurography sequence with tractography is still a work in progress, able to demonstrate nerves tracts, their structure alteration or deformation due to pathologic processes surrounding or located along the postganglionic brachial plexus. It may become a precious tool for the understanding of the underlying molecular pathophysiologic mechanisms in diseases affecting the brachial plexus and may play a role for

surgical planning procedures in the near future ***(Vargasa et al., 2010).***

Finally, MRI has become increasingly important in the evaluation of brachial plexus pathology, as the technology and resolution has improved. Correlation of imaging results with electrophysiologic findings increases overall specificity and sensitivity. EMG and MRI examinations are complementary.

Muscle and nerve biopsies are diagnostic tools of great potential in the diagnosis of neuromuscular diseases. When performed properly, it can yield information of great benefit to the patient and clinician and serve as a basis for providing treatment, genetic counseling, and prognostic information.

MRI is a promising tool that can be used as an adjunctive test during the evaluation of patients who have myopathy and can help raise the diagnostic yield of a planned biopsy. It also has promise as a clinical endpoint.

Recommendations

1. More research is required to quantify further the potential usefulness of MRI as an endpoint in therapeutic trials in neuromuscular disease.

2. There are few well-documented reports of MRI findings in congenital myopathies so, future studies will be needed to focus on that subject.

3. We need to perform sequential studies in order to follow the progression of muscle involvement in progressive disorders. This would allow us to obtain information not only about the state and progression of the pathology of individual muscles, but also more generally about the natural history of the conditions studied.

4. These data can provide an important baseline for ongoing therapeutic studies, such as those using antisense oligonucleotides in patients with DMD. The opportunity to assess the progression of pathological changes in individual muscles in treated and untreated patients using contrast-agent-enhanced MRI may provide valuable information on the efficacy of the treatment and may represent an alternative to serial muscle biopsies.

5. Future studies will need to focus on the DW neurography sequence with tractography. It may become a precious tool for the understanding of the underlying molecular pathophysiologic mechanisms in diseases affecting the brachial plexus and may play a role for surgical planning procedures in the near future.

6. Finally, various agents, such as superparamagnetic iron oxides (SPIO), are being used to label cells for in vivo monitoring by MRI. Such techniques will be particularly useful for labeling cells for in vivo MRI tracking of muscle stem cells.

Summary

The peripheral nervous system is composed of multiple cell types and elements that subserve diverse motor, sensory, and autonomic functions. Peripheral neuropathy and polyneuropathy are terms that describe syndromes resulting from diffuse lesions of peripheral nerves, usually manifested by weakness, sensory loss, pain, and autonomic dysfunction. Mononeuropathy indicates a disorder of a single nerve often resulting from local trauma, compression, or entrapment. Mononeuropathy multiplex signifies focal involvement of two or more nerves, usually as a result of a generalized disorder such as diabetes mellitus or vasculitis. Neuritis is typically reserved for inflammatory disorders of nerves resulting from infection or autoimmunity.

Myopathies are diseases of skeletal muscle which are not caused by nerve disorders. These diseases cause the skeletal or voluntary muscles to become weak or wasted. It can be caused by inherited genetic defects (e.g., muscular dystrophies), or by endocrine, inflammatory (e.g., polymyositis), and metabolic disorders.

Muscle and nerve biopsies can be extremely useful in the evaluation of patients with myopathies and neuropathies. The interpretation of a nerve biopsy requires correlation of histological changes, with clinical information including the results of electrophysiological investigations.

The major indications for nerve biopsy are when vasculitis or amyloidosis are strongly suspected. Additional indications for nerve biopsy include other autoimmune inflammatory conditions, possible infectious processes (e.g., leprosy), and tumor infiltration (e.g., perineurioma). Less commonly, nerve biopsy may be warranted to diagnose uncommon forms of hereditary neuropathy when DNA testing is not available or is negative.

At present, muscle biopsy is an essential part of the diagnostic investigation of most categories of muscle diseases, including inflammatory and many metabolic and congenital myopathies, as well as many of the muscular dystrophies.

Muscle biopsy is somewhat complex in that an optimal outcome requires coordination of the clinician, surgical team, pathologist, and technical staff in the pathology laboratory.

The changes that can be demonstrated in muscle using conventional imaging techniques are limited. Fat atrophy may be apparent on plain radiography, while US can be used to identify different patterns of involvement in patients with primary muscle disorders or neurogenic disorders. Also, it can be used to guide muscle biopsies by selecting relatively spared muscles.

CT has been extensively used to distinguish patterns of selective muscle involvement in muscular dystrophies. MRI techniques have shown that MRI has a higher sensitivity than

CT for identifying early fatty replacement in muscles, and provides better anatomical details.

MRI of the muscle can be useful in for many reasons. Just as EMG can be useful in demonstrating objective evidence of muscle dysfunction, MRI can provide clear evidence of organicity, assisting the ordering physician in deciding which patients are likely to benefit from a muscle biopsy. Once the decision is made to proceed with muscle biopsy, MRI is valuable in selecting which muscle is most likely to reveal a pathologic diagnosis and can minimize false-negative biopsies. MRI may be valuable in distinguishing between conditions with similar presentations, especially in conditions with phenotypic variability.

There is accumulating evidence that muscle MRI can be a valuable additional tool for diagnosing inherited neuromuscular disorders.

DMD is an X-linked disorder characterized by progressive weakness of skeletal muscle.

The diagnosis of DMD is generally suspected on muscle biopsy that shows absence of dystrophin on immunohistochemical staining, and it is confirmed by genetic screening for mutations in the dystrophin gene. Muscle MRI allows one to evaluate the progression of muscle involvement as it evolves over time.There is selective muscle involvement.

The pattern of selective muscle involvement in individuals with Becker MD, a milder form that is also secondary to mutations in the same gene, is similar to the one observed in DMD, but milder, in keeping with the observed clinical course.

Congenital muscular dystrophy is an uncommon genetically determined, relatively nonprogressive necrotizing myopathy. This dystrophy is characterized by hypotonia, multiple joint contractures, and generalized muscular weakness, with more severity proximally than distally.

The overall involvement of muscle in congenital dystrophy can be reliably depicted on MR imaging, The sartorius and gracilis muscles are relatively spared in the thighs. Histologic features of this disorder are typical of muscular dystrophy, consisting of fibrosis and fat replacement with marked variability in fiber size, although usually without active fiber necrosis and regeneration.

LGMDs are a genetically heterogeneous group of disorders that are characterized clinically by predominant proximal muscle weakness affecting mainly the hip girdle, elevated creatinine kinase levels, and dystrophic changes on muscle biopsy.

At the thigh level, patients with LGMD2A and LGMD2I both have predominant involvement of the adductor magnus and the posterior thigh muscles; however, there is more substantial involvement of muscles of the anterior compartment

in LGMD2I, and a significant hypertrophy of the sartorius and gracilis muscles. At the calf level, patients with LGMD2I have variable involvement of the calf muscles, with predominant involvement of the posterior muscles, but without the striking differential involvement between the medial and the lateral head of the gastrocnemius observed in LGMD2A.

Emery-Dreifuss muscle dystrophy is characterized by slowly progressive weakness and early contractures of the elbows and Achilles tendons, with rigidity of the spine and invariable cardiac involvement.

Muscle MRI can help to identify distinct patterns of muscle involvement in the two forms (the X-linked form and the dominant form) While patients with the X-linked form have minimal involvement at thigh level, patients with the dominant form often have a moderate to severe selective involvement of the vastus lateralis and intermedius, which in some cases is associated with involvement of the adductor magnus.

Myotonic muscular dystrophy is inherited as an autosomal dominant trait. The disease affects several organ systems and is characterized by myotonia, weakness and wasting of muscles, Common findings in MRI include increased thickness of the subcutaneous fat associated with a decrease in muscle thickness.

Inflammatory myopathies are acquired primary diseases of the striated muscles characterized by muscle weakness, inflammatory changes, and frequently elevated levels of serum

muscle enzymes. Together with inclusion body myositis, dermatomyositis and PM are the most common diseases of the striated muscle, skin, and surrounding connective tissue. Despite the underlying autoimmune dysfunction, each entity has unique clinical and histologic features.

Polymyositis is an immune-mediated syndrome secondary to defective cellular immunity that is most commonly associated with other systemic autoimmune diseases. Muscle biopsy is the definitive test not only for establishing the diagnosis of polymyositis but also for excluding other neuromuscular diseases. In polymyositis, inflammation is the histologic hallmark of the disease. The endomysial infiltrates are mostly in foci in the fascicles, initially surrounding healthy muscle fibers and finally invading these cells and resulting in phagocytosis and necrosis.

MRIs show signal intensity abnormalities of muscle due to inflammation, edema, or scarring. Images may be used to guide muscle biopsy.

Dermatomyositis is considered to be the result of a humoral attack against the muscle capillaries and small arterioles

Findings on muscle biopsy can be diagnostic. Although inflammation is the histologic hallmark of dermatomyositis, polymyositis, and inclusion-body myositis, dermatomyositis is the only disease that shows perifascicular atrophy.

MRI may be useful in assessing for the presence of an inflammatory myopathy in patients without weakness. Chest radiography should be obtained at the time of diagnosis and when symptoms develop.A barium swallow allows evaluation of esophageal dysmotility. US of the muscles has been suggested for evaluation but has not been widely accepted. CT scanning is useful in the evaluation of potential malignancy that might be associated with inflammatory myopathy.

IBM is characterized clinically by the insidious onset of slowly progressive proximal and distal weakness, CT or MRI imaging of muscles may be useful in helping diagnose difficult cases. Findings involve selective atrophy of the quadriceps and forearm flexors.

Muscle biopsy sample shows myopathic changes with varying degrees of inflammation, predominantly within the endomysium.

Congenital myopathies are a group of disorders defined largely on the basis of the pathologic findings within muscle. Most of these conditions share common clinical features, including onset in early life, nonprogressive or slowly progressive course, proximal or generalized muscle weakness, and hypotonia. They include:

In central core myopathy, the characteristic histological features are the structural alterations within the center of muscle fibers. MRI shows a consistent pattern of selective muscle involvement in the thighs and lower legs.

On routine histochemistry, the nemaline rods appear as small, red-staining bodies in the subsarcolemma and occasionally perinuclear regions Patients with nemaline myopathy have highly heterogeneous findings on muscle MRI corresponding to the wide range of clinical phenotypes and genes that have been reported.

While in centronuclear myopathy, muscle biopsies reveal myonuclei in the center of muscle fibers, Muscle MRI show a characteristic progressive sequence with early involvement of the ankle plantar flexors and subsequent signal changes within the hamstring muscles and, finally, the anterior thigh.

Medical imaging is playing an increasingly important role in the diagnosis of disorders affecting the peripheral nerves. Plain radiographs, US, CT, all have limited role in diagnosis of Peripheral Nerve Diseases

Recently, MR neurography enables the physician to examine the peripheral nerve for anatomic abnormalities. The intrinsic contrast properties of adipose tissue and both endoneurial and axoplasmic fluid allow distinct MR imaging of peripheral nerves.

Typical MR peripheral nerve imaging protocols use high-resolution spin-echo T1-weighted images to show anatomic detail and fat-suppressed T2-weighted or STIR images to detect abnormal nerve signal intensity.

DW MR neurography may provide improved contrast between the nerves of the brachial plexus and the surrounding tissues. Diffusion tensor imaging and tractography of peripheral nerves, is based on the principle that water molecules have anisotropic diffusion properties in white matter fiber tracts, compared with isotropic diffusion in surrounding tissues.

More recently, the 3D STIR SPACE sequence is mainly used to rapidly image the postganglionic nerve roots of the entire brachial plexus. It is useful for the initial screening of patients with neoplastic conditions involving the brachial plexus and it is a valuable adjunct in the depiction of nerve site compressions.

The disease	Image finding
Muscle diseases	
DMD	Symmetric and selective involvement of the proximal pelvic girdle muscles in the early stage of the disease process, and the calf and proximal shoulder girdle muscles in the late stage. Pseudohypertrophy of the calves is present in 80% of patients.
BMD	Selective muscular involvement. Enlargement of the calves due to fatty infiltration, but it is less severe than in Duchenne's muscular dystrophy.
CMDs	Diffuse involvement of all the posterior and lateral muscles of the thigh with selective sparing of the sartorius, gracilis, and adductor longus, and often the rectus femoris.
LGMDs	Striking and early involvement of the posterior thigh muscles.
Emery Dreifuss MD	Patients with the X-linked form have minimal involvement at thigh level, patients with the dominant form often have a moderate to severe selective involvement of the vastus lateralis and intermedius, which in some cases is associated with involvement of the adductor magnus.
Myotonic muscular dystrophy	Common findings include increased thickness of the subcutaneous fat associated with a decrease in muscle thickness. The sternocleidomastoid muscle is affected early in the disease course and demonstrates striking atrophy.
Polymyositis	MRI accurately documents the extent and intensity of the muscle abnormalities. The inflammation is usually symmetric and classically involves the proximal muscle groups.
Dermatomyositis	The subcutaneous connective tissue septa and sometimes even the muscle fasciae are also involved.

Inclusion body myositis	MRI showed marked muscle wasting and fatty infiltration. The quadricipital group of thighs was predominantly affected as compared with the flexor compartment.
Congenital myopathy	
- CCD	consistent pattern of selective muscle involvement in the thighs and lower legs
- *Nemaline Myopathy*	Little or no involvement of the thigh muscles, with selective involvement of the rectus femoris. At calf level there is early involvement of the tibialis anterior.
- Centronuclear (myotubular) myopathy	Characteristic progressive sequence with early involvement of the ankle plantarflexors and subsequent signal changes within the hamstring muscles and, finally, the anterior thigh.
- MmD	The pattern of selective involvement on muscle imaging is similar to that observed in classic CCD.
Nerve Diseases	
GBS	Lumbosacral MRI can show enhancement of the nerve roots with gadolinium. Selective anterior nerve root enhancement appears to be strongly suggestive of GBS.
CIDP	MRI of the spine with gadolinium enhancement may show enhancement of nerve roots. Root hypertrophy can be shown by MRI at the lumbar or cervical level.
Inherited neuropathies	MRI can demonstrate enlarged nerves, not only at the level of the spinal roots but also in the limbs, which may help in distinguishing hereditary from acquired demyelinating neuropathy.
Leprous neuropathy	High-frequency linear ultrasonographic probes can be used to demonstrate thickening of nerves and presence of osseofibrous compression.

References

Aaron G. Filler, MD, PhDa, Kenneth R. Maravilla, MDb, Jay S. Tsuruda, MDc (2004): MR neurography and muscle MR imaging for image diagnosis of disorders affecting the peripheral nerves and musculature. Neurol Clin 22 (2004) 643–682.

Amato AA and Dumitru D (2002): Acquired neuropathies. In Dumitru D, Amato AA, Swartz MJ (eds). Electrodiagnostic Medicine, 2nd edn. Philadelphia: Hanley & Belfus, 2002, pp. 937–1041.

Amgad Saddik Hanna, James S Harrop, Dachling Pang, Kamran Sahrakar, Robert J Spinner (2009): Nerve Entrapment Syndromes. eMedicine Specialties > Neurosurgery > Miscellaneous.

Andrew C Miller, Razi M Rashid, Richard H Sinert (2010): Guillain-Barre Syndrome: Differential Diagnoses & Workup. eMedicine Specialties > Emergency Medicine > Neurology.

Anthony A. Amato, MD, James A. Russell, DO. (2008): Neuroomuscular disorders; 2:73-76.

Anthony AA and James AR. (2008): Neuromuscular Disorders. Muscle and Nerve Histopathology Chapter

3 and Muscle dystrophy Chapter 24: 3p71-83 and p529-570.

Askanas V and Engel WK. (2007): Inclusion-body myositis, a multifactorial muscle disease associated with aging: current concepts of pathogenesis. Curr Opin Rheumatol; 19:550.

Astrea G, Schessl J, Clement E, Tosetti M, Mercuri E, Rutherford M, Cioni G, B nnemann CG,. Muntoni F, Battini R. (2009): Muscle MRI in FHL1-linked reducing body myopathy. Neuromuscular Disorders 19 (2009) 689–691.

Banker BQ, Engel AG. (2004): Basic reactions of muscle. In Engel AG, Franzini-Armstrong C (eds). Myology, 3rd edn. New York: McGraw-Hill, pp. 691–747.

Bertorini TE, Horner LH. (2002): Histology and histochemistry of muscle and nerve. In: Bertorini TE, ed. Clinical evaluation and diagnostic tests for neuromuscular disorders. Amsterdam: Butterworth-Heinemann, Elesevier Science 2002:595-691.

Brian S Tseng, Sarah Sheikh, Jennifer A Markowitz (2009): Guillain-Barre Syndrome in Childhood: Differential Diagnoses & Workup eMedicine Specialties > Neurology > Pediatric Neurology

Calado A, Tome FM, Brais B, et al. (2000): Nuclear inclustions in oculopharyngeal muscular dystrophy consist of poly (A) binding protein 2 aggregates which sequester poly(A) RNA. Hum Mol Genet.; 9:2321-2328.

Carsten B and Dr Joachim S (2007): Reproduced from Schessl et al., Neuromuscular Disorders 2007; 17:28–32, with permission from Elsevier).

Cartwright MS, Chloros GD, Walker FO, Wiesler ER, Campbell WW. (2007): Diagnostic ultrasound for nerve transaction Muscle Nerve; 35:796–799.

Charles E. Alpers, Douglas CA, James MC, Umberto De Girolami, et al. (2009): Kumar: Robbins and Cotran Pathologic Basis of Disease, Professional Edition, 8th ed; Chapter 27 - Peripheral Nerve and Skeletal Muscle.

Charles S. Abrams, Mark J. Abzug, Paul C. (2010): Adams, Tod C. Aeby, Gorav Ailawadi, Lee Akst, Bope: Conn's Current Therapy, 1st ed. section 14 - The Nervous System. Peripheral Neuropathies.

Cohn RD and Campbell KP. (2000): Molecular basis of muscular dystrophies. Muscle Nerve;23(10):1456–1471.

Collins MP, Mendell JR, Periquet MI, et al. (2000): Superficial peroneal nerve/peroneus brevis muscle biopsy in vasculitic neuropathy. Neurology. 2000;55:636-643

Cynthia K. Aaron, Jean T. Abbott, Riyad B. Abu-Laban, Bruce D. Adams (2009): Marx: Rosen's Emergency Medicine, 7th ed. Copyright © 2009 Mosby, An Imprint of Elsevier Ch105 peripheral nerve disorders.

Dahlbom K, Lindberg C, Oldfors A. (2002): Inclusion body myositis: morphological clues to correct diagnosis. Neuromuscul Disord.; 12:853-857.

Daniele T, Emiliano A, Letizia R, Marzia Cand Paolo F (2007): Magnetic resonance imaging for paraneoplastic dermatomyositis MJA 2007; 187 (10): 589.

Day JW, Ricker K, Jacobsen JF. (2003): Myotonic dystrophy type 2: molecular, diagnostic and clinical spectrum. Neurology.; 60:657-664.

De Girolami U, Frosch M, Amato AA. (2003): Biopsy of nerve and muscle. In Samuels M, Feske S (eds). Office Practice of Neurology, 2nd edn. Philadelphia: Harcourt Health Sciences, pp. 217–225.

Dent KM, Dunn DM, von Niederhausern AC, et al. (2005): Improved molecular diagnosis of dystrophinopathies in

an unselected clinical cohort. Am J Med Genet A. Apr 30; 134(3):295-8. [Medline].

Divakara Kedlaya (2009): Charcot-Marie-Tooth Disease: Differential Diagnoses & Workup. eMedicine Specialties > Physical Medicine and Rehabilitation > Peripheral Neuropathy

Dyck PJ, Dyck PJB, Engelstad J. (2005): Pathologic alterations of nerves. In: Dyck PJ, Thomas PK (eds). Peripheral Neuropathy, 4th edn. Philadelphia: W B Saunders, pp. 733–829.

Engel AG. (2004): The muscle biopsy. In Engel AG, Franzini-Armstrong C (eds). Myology, 3rd edn. New York: McGraw-Hill, 2004, pp. 681–690.

Eugenio M, Sonia M Marika P, Anna P, Joanna A, Francesco M. (2007): Muscle MRI in Inherited Neuromuscular Disorders: Past, Present, and Future. Journal of Magnetic Resonance Imaging 25:433–440.

Faccioli N, Foti G, Comai A, Cugini C, Guarise A, Mucelli RP. (2009): MR imaging findings of elastofibroma dorsi in correlation with pathological features: our experience. Radiol Med. 2009 Dec;114(8):1283-91. Epub 22.

Ferreiro A, Fardeau M. (2002): 80th ENMC international workshop 12–13th May, 2000, Soestduinen, the Netherlands. Neuromuscul Disord; 12(1):60–68.

Fischer D, Walter MC, Kesper K, et al. (2005): Diagnostic value of muscle MRI in differentiating LGMD2I from other LGMDs. J Neurol; 252:538–547.

Fleckenstein JL (2000): MRI of neuromuscular disease: The basics. Semin Musculoskelet Radiol; 4:393-419.

Francisco de Assis AG and Thomas HB (2010): Dermatomyositis/Polymyositis: Differential Diagnoses & Workup. eMedicine Specialties > Neurology > Neuromuscular Diseases; Updated: Mar 8, 2010.

Francisco de Assis Aquino Gondim, Gisele Oliveira, Florian P Thomas (2009): Hereditary Neuropathies of the Charcot-Marie-Tooth Disease Type. eMedicine Specialties > Neurology > Neuromuscular Diseases.

FreundW, Brinkmann A, Wagner F, et al. (2007): MR neurography with multiplanar reconstruction of 3D MRI datasets: an anatomical study and clinical applications. Neuroradiology 2007;49:335–341.

Gautschi OP, Land M, Hoederath P, Fournier JY, Hildebrandt G, Cadosch D. (2010): [Carpal tunnel syndrome - modern diagnostic and management.].3;99(3):163-73. German.

Glenn Lopate (2009): Congenital Myopathies. eMedicine Specialties > Neurology > Pediatric Neurology.

Grant GA, Britz GW, Goodkin R, Jarvik JG, Maravilla K, Kliot M. (2002): The utility of magnetic resonance

imaging in evaluating peripheral nerve lesions. Muscle Nerve; 25:314–331.

Greenberg SA, Pinkus JL, et al. (2005): Interferon-alpha/betamediated innate immune mechanisms in dermatomyositis. Ann Neurol; 57(5):664–678.

Grisold W, Piza-Katzer H, Jahn R, Herczeg E. (2002): Intraneural nerve metastasis with multiple mononeuropathies. J Peripher Nerv Syst; 5(3):163–167.

Gustav A, David WC, Doris B, Borut M, and Dominik W (2006): Peripheral Neuropathies of the Median, Radial, and Ulnar Nerves: MR Imaging Features1. RSNA.

Hackman P, Vihola A, Haravouri H. et al. (2002): Tibial muscular dystrophy (TMD) is a titinopathy caused by mutations in TTN, the gene encoding for the giant skeletal muscle protein titin. Am J Hum Genet 2002; 71:492-500.

Halford H, Graves A, Bertorinie T. (2000): Muscle and nerve imaging techniques in neuromuscular diseases. J Clin Neuromusc Dis;2:41–51.

Heinz J, Carina Wallgren-Pettersson and Jocelyn L. (2008): Centronuclear (myotubular) myopathy. *Orphanet Journal of Rare Diseases*, **3:**26doi:10.1186/1750-1172-3-26.

Heinz Jungbluth (2007): Multi-minicore Disease. Orphanet J Rare Dis. 2007; 2: 31. Published online 2007 July 13. doi: 10.1186/1750-1172-2-31.

Helen CL, Paul EB, **Michael PC**, **Isabel PC**. **(2010):** Inclusion Body Myositis: Differential Diagnoses & Workup. eMedicine Specialties > Neurology > Neuromuscular Diseases; Updated: Jun 11, 2010.

Hilton DA, Jacob J, Househam L, Tengah C. (2007): Complications following sural and peroneal nerve biopsies. J Neurol Neurosurg Psychiatry; 78:1271–1272.

Hiltunen, J., Suortti, T., Arvela, S. et al. (2005): Diffusion tensor imaging and tractography of distal peripheral nerves at 3 T, Clin Neurophysiol, vol. 116, pp. 2315-2323.).

Hoffman EP, Fischbeck KH, et al. (1988): Characterization of dystrophin in muscle-biopsy specimens from patients with Duchenne's or Becker's muscular dystrophy. N Engl J Med; 318(21):1363–1368.

Hu W, Dehmel T, Pirhonen J et al. (2006): Interleukin 23 in acute inflammatory demyelination of the peripheral nerve. Arch Neurol; 63:658-664.

Hughes RA, Allen D, Makowska A, Gregson NA. (2006): Pathogenesis of chronic inflammatory demyelinating,

polyradiculoneuropathy. J Peripher Nerv Syst;11(1): 30–46.

Ikeda K, Kinoshita M, Iwasaki Y, et al. (2002): Unusual fatty infiltration of the soleus muscle in a patient with congenital nemaline myopathy: fat-suppression muscle MRI. Intern Med.; 41:237-240.

Jean-Michel V, Claudia S, Laurent M (2010): Chronic inflammatory demyelinating poly-radiculoneuropathy: diagnostic and therapeutic challenges for a treatable condition. The Lancet Neurology - Volume 9, Issue 4 - Copyright © 2010 Elsevier - About This Journal.

Jeannet PY, Bassez G, et al. (2004): Clinical and histologic findings in autosomal centronuclear myopathy. Neurology; 62(9):1484–1490.

Jeffrey C. Allen, Abdulrahim M. Alshehri, Anthony A. Amato, Michael J. Aminoff, Bradley: Neurology in Clinical Practice, 5th ed. (2008): Bradley: Neurology in Clinical Practice, 5th ed. 2008 Butterworth-Heinemann, An Imprint of Elsevier Ch 45D Truma of the nervous system: EVALUATION OF NERVE TRAUMA Vol 2: the neurological disorders ,part3:neurological diseases.

Jeffrey CA, Abdulrahim MA, Anthony AA, Michael JA Ashwal (2008): Bradley: Neurology in Clinical

Practice, 5th ed. CHAPTER83– Disorders of Skeletal Muscle 2403- 2407.

Jeffrey P Callen (2009): Dermatomyositis: Differential Diagnoses & Workup eMedicine Specialties > Rheumatology > Systemic Rheumatic Disease. Updated: Apr 14, 2009.

Jeroen Hendrikse, Tomohiro Y, Willem PTM, Mali, Thomas C. Kwee, Yutaka Imai, and Peter R. LuijteTaro Takahara. (2008): Diffusion-weighted MR Neurography of the Brachial Plexus: Feasibility Study; RSNA.

Joachim S and Carsten Boennemann (2007): Neuromuscular Disorders; 17:28–32, with permission from Elsevier.

John WA, David CA, Syed MA, Daniel A, Louis FA, Gregory JA. (2007): Neurologic Conditions Rakel: Textbook of Family Medicine, 7th ed:54.

Jungbluth H, Davis MR, Muller C, et al. (2004): Magnetic resonance imaging of muscle in congenital myopathies associated with RYR1 mutations. Neuromuscul Disord;14:785–790.

Jungbluth H, Sewry CA, Counsell S, et al. (2004): Magnetic resonance imaging of muscle in nemaline myopathy. Neuromuscul Disord; 14:779–784.

Katiriji B and Tarakad S (2007): Metabolic Myopathies. eMedicine Specialties > Neurology > Neuromuscular Diseases. Updated: Jul 9, 2009.

Kieseier BC, Hartung HP, Wiendl M. (2006): Immune circuitry in the peripheral nervous system. Curr Opin Neurol ; 19:437-445.

Koller N (2005): Engl J Med;352(13): 1343–1356, Fig. 3, p. 1350.

Lacomis D. (2005): Clinical utility of peripheral nerve biopsy. Curr Neurol Neurosci Rep 2005;5(1):41–47.

Laporte J, Biancalana V, et al. (2000): MTM1 mutations in X-linked myotubular myopathy. Hum Mutat; 15(5):393–409.

Larry ED, Molly KK, Jessica LS. (2005): Fundamentals of Neurologic disease; 6:57.

Leroy-Willig A, Willig TN, Henry-Feugeas MC, et al. (1997): Body composition determined with MR in patients with Duchenne muscular dystrophy, spinal muscular atrophy, and normal subjects. Magn Reson Imaging; 15:737 -744[Medline]

Lewis PR, Timothy AP, Gary MA. (2010): Merritt's Neurology, 12th Edition;140:**p858** myopathies.

Lewis PR, Timothy AP, Gary MA. (2010): Periphral Neuropathis. Merritt's Neurology; 12th Edition; 132:814.

Lopate G and Glenn L (2007): Congenital Myopathies; eMedicine Specialties > Neurology > Pediatric Neurology. Updated: May 26, 2009

Lopate G and Glenn L. (2009): Congenital Muscular Dystrophy; eMedicine Specialties > Neurology > Neuromuscular Diseases. Updated: Feb 12, 2010

M.I. Vargasa, , M. Viallonb, D. Nguyena, J.Y. Beaulieuc, J. Delavellea, M. Beckerd (2010): New approaches in imaging of the brachial plexus. European Journal of Radiology; 74: 403–410.

Mahjneha, Lamminenc A and Tuominen H (2007): Episodic muscle pain, stiffness, and weakness associated with tubular aggregates and myoedema. European Journal of Neurology; 14: 569–571.

Manji H. (2000): Neuropathy in HIV infection. Curr Opin Neurol.;13:589-592.

Maravilla KR, Bowen BC. (1998): Imaging of the peripheral nervous system: evaluation of peripheral neuropathy and plexopathy. Am J Neuroradiol.; 19:1011-1023.

Mark D, Andrew J. and Grainger (2008): Adam: Grainger & Allison's Diagnostic Radiology, 5th ed. Copyright © 2008 Churchill Livingstone, An Imprint of Elsevier Volume 2 SECTION FIVE – The musculoskeletal system CHAPTER 45 – Techniques and Imaging of Soft Tissues A. NEUROMUSCULAR DISORDERS.

Mathews KD, Moore SA. (2004): Multiminicore myopathy, central core disease, malignant hyperthermia susceptibility, and RYR1 mutations: One disease with many faces? Arch Neurol; 61(1):27–29.

Maximilian S, Ina K, Ulrike E, Michael F, Nikolay T, Claus DC and Marius Horger1 (2009): MRI Findings in Inflammatory Muscle Diseases and Their Noninflammatory Mimics AJR 2009; 192:1708-1716 © American Roentgen Ray Society.

McLeod JG. (1995): Investigation of peripheral neuropathy. J Neurol Neurosurg Psychiatry.;58:274-283.

Mellion M. and Brian S Tseng (2009): Dystrophinopathies. eMedicine, February. eMedicine Specialties > Neurology > Neuromuscular Diseases. Updated: Feb 26, 2009.

Meola G. (2000): Genetic and clinical heterogeneity in myotonic dystrophies. Muscle Nerve 2000;13:1789–1799.

Mercuri E, Bushby K, Ricci E et al. (2005): Muscle MRI findings in patients with limb girdle muscular dystrophy with calpain 3 deficiency (LGMD2A) and early contractures. Neuromuscul Disord;15: 164–171.

Mercuri E, Pichiecchio A, Counsell S, et al. (2002): A short protocol for muscle MRI in children with muscular dystrophies. Eur J Paediatr Neurol; 6:305–307.

Michael D, Milne A, FRCPDavid C, Alastair C et al. (2001): Brain's Diseases of the Nervous System Polyneuropathy 12,381.

Michelle L. et al. (2009): Mellion eMedicine Specialties > Neurology > Neuromuscular Diseases. Updated: Feb 26.

Midroni G and Bilbao *J*M, eds. (1995): Biopsy diagnosis of peripheral neuropathy. Boston: Butterworth-Heinemann 1995:31-53

Midroni G and Bilbao JM. (1995): Biopsy diagnosis of peripheral neuropathy. Boston: Butterworth-Heinemann; 31-53.

Midroni G and Bilbao JM. (1995): eds. Biopsy diagnosis of peripheral neuropathy. Boston: Butterworth-Heinemann: 31-53.

Mimori T et al. (2007): Autoantibodies in idiopathic inflammatory myopathy: an update on clinical and pathophysiological significance. Curr Opin Rheumatol; 19:523.

Moghadaszadeh B, Petit N, Jaillard C et al. (2001): Mutations in SEPN1 cause congenital muscular dystrophy with spinal rigidity and restrictive respiratory syndrome. Nat Genet; 29:17-18.

Moore KR, Tsuruda JS, Dailey AT. (2001): The value of MR neurography for evaluating extraspinal neuropathic leg pain: a pictorial essay. Am J Neuroradiol.;22:786-794.

Needham M, et al. (2007): Genetics of inclusion-body myositis. Muscle Nerve; 35:549.

Nelis E, Timmerman V, De Jonghe P, Van Broeckhoven C, Rautenstrauss B. (1999): Molecular genetics and biology of inherited peripheral neuropathies: a fast-moving field. Neurogenetics.; 2:137-148.

Nezam HA, Masood A, Cem A, Ban MA (2007): Goldman: Cecil Medicine, 23rd ed. Copyright © 2007 Saunders, An Imprint of Elsevier Chapter 446 – Peripheral Neuropathies.

Nezam HA, Masood A, Cem A, Ban MA. (2007): Peripheral Neuropathies Goldman: Cecil Medicine **23rd ed;** 446.

Ozsarlak O, Schepens E, Parizel PM, et al. (2001): Hereditary neuromuscular diseases. Eur J Radiol; 40:184–197.

Peters SA, Köhler C, Schara U, Hohendahl J, Vorgerd M, Nicolas V, Heyer CM. (2007): [Muscular magnetic resonance imaging for evaluation of myopathies in children]. Klin Padiatr. 2008 Jan-Feb; 220(1):37-46. Epub 21. Review. German.

Prior TW, Bartolo C, et al. (1995): Spectrum of small mutations in the dystrophin coding region. Am J Hum Genet 1995;57(1):22–33.

Quinlivan RM, Muller CR, et al. (2003): Central core disease: Clinical, pathological, and genetic features. Arch Dis Child; 88(12):1051–1055.

Ramesh P and Mythili S (2009): Polymyositis: Differential Diagnoses & Workup UeMedicine Specialties > Rheumatology > Systemic Rheumatic Disease. pdated: Nov 6, 2009.

Ranque-Francois B, Maisonobe T, Dion E, Piette J-C, Chauveheid M-P, Amoura Z, Papo T. (2005): Familial inflammatory inclusion body myositis Ann Rheum Dis; 64:634–637.

Richard A Lewis (2010): Chronic Inflammatory Demyelinating Polyradiculoneuropathy: Differential

Diagnoses & Workup. eMedicine Specialties > Neurology > Neuromuscular Diseases

Sabin TD, Swift TR, Jacobson RR (1993): *Leprosy*. In: Dyck PJ, Thomas PK, ed. *Peripheral Neuropathy*, Philadelphia: WB Saunders.

Sabina RL. (2000): Myoadenylate deaminase deficiency. A common inherited defect with heterogeneous clinical presentation. Neurol Clin.; 18:185-194.

Said G. (1999): Vasculitic neuropathy. Curr Opin Neurol.;12:627-629.

Schessl J, Medne L, Hu Y, Zou Y, Brown MJ, Huse JT, Torigian DA, Jungbluth H, Goebel HH, Bönnemann CG: (2007): MRI in DNM2-related centronuclear myopathy: evidence for highly selective muscle involvement. Neuromuscul Disord; 17(1):28-32. PubMed Abstract.

Schoser BG, Frosk P, et al. (2005): Commonality of TRIM32 mutation in causing sarcotubular myopathy and LGMD2H. Ann Neurol; 57(4):591–595.

Scollard DM, Adams LB, Gillis TP, Krahenbuhl JL, Truman RW, Williams DL. (2006): The continuing challenges of leprosy. Clin Microbiol Rev.; 19(2):338-81. [Medline]

Scott DL and Kingsley GH. (2004): Use of imaging to assess patients with muscle disease. Curr Opin Rheumatol;16(6):678-83.

Shelly MJ, Hodnett PA, MacMahon PJ, Moynagh MR, Kavanagh EC, Eustace SJ. (2009): MR imaging of muscle injury. Magn Reson Imaging Clin N Am.; 17(4):757-73, vii. Review.

Shen J, Zhou CP, Zhong XM, Guo RM, Griffith JF, Cheng LN, Duan XH, Liang BL. (2010): Arch is focused: MR Neurography: T1 and T2 Measurements in Acute Peripheral Nerve Traction Injury in Rabbits. RSNA. Radiology; 254(3):729-38.

Sridharan Ramaratnam, Lakshmi Narasimhan Ranganathan (2010): Leprosy: Differential Diagnoses & Workup. eMedicine Specialties > Neurology > Neurological Infections.

Sudhakar RS, **Christopher** C, **Ajit** B, **Steven PM, Robert (2009):** Brachial Plexus, MRI. eMedicine Specialties > Radiology > Brain/Spine; Updated: Jun 8, 2009.

Takashima H, Boerkoel CF, De Jonghe P, Ceuterick C, Martin JJ, Voit T, et al. (2002): Periaxin mutations cause a broad spectrum of demyelinating neuropathies. Ann Neurol.;51:709-715.

Tarakad SR, MBBS, FRCP, Richard A Sater (2009): Acute Inflammatory Demyelinating Polyradiculoneuropathy:

Differential Diagnoses & Workup. eMedicine Specialties > Neurology > Neuromuscular Diseases.

Taro T, Jeroen H, , Tomohiro Y, Willem PT, Mali, Thomas C. Kwee, Yutaka Imai, and Peter RL. (2008): Diffusion-weighted MR Neurography of the Brachial Plexus: Feasibility Study. RSNA.

Timothy CP and Thomas HB (2009): Charcot-Marie-Tooth and Other Hereditary Motor and Sensory Neuropathies: Differential Diagnoses & Workup. eMedicine Specialties > Neurology > Neuromuscular Diseases

Twee Do (2009): Muscular Dystrophy eMedicine Specialties > Orthopedic Surgery > Pediatrics; Updated: Mar 31, 2009.

Van ES, Vernino S, Low PA, et al. (2000): Autoantibodies to ganglionic acetylcholine receptors in autoimmune autonomic neuropathy. N Engl J Med; 343:847–845.

Vargas MI, Viallon M, Nguyen D, Beaulieu JY, Delavelle J, Beckerd M. (2010): New approaches in imaging of the brachial plexus. European Journal of Radiology 74: 403–410.

Venu A, Joseph TA, Eduardo A, Karen AFA, Frontera (2008): Essentials of Physical Medicine and Rehabilitation, 2nd ed. Chapter 133 – Peripheral Neuropathies**.**

Viallon M, Vargas MI, Jlassi H, L ϑblad KO, Delavelle J. (2008): High-resolution and functional magnetic resonance imaging of the brachial plexus using an isotropic. 3DT2 STIR (short term inversion recovery)SPACEsequence and diffusion tensor imaging. Eur Radiol; 18(May (5)):1018–23.

Vogel H and Zamecnik J. (2005): Diagnostic immunohistology of muscle diseases. *J Neuropathol Exp Neurol*. Mar; 64(3):181-93. [Medline].

Walker FO, Cartwright MS, Wiesler ER, Caress J. (2004): Ultrasound of nerve and muscle. Clin Neurophysiol; 115:495–507.

Walker UA. (2008): Imaging tools for the clinical assessment of idiopathic inflammatory myositis. Curr Opin Rheumatol; 20(6):656-61.

Wallgren-Pettersson C. (2005): Congenital myopathies. Eur J Paediatr Neurol 2005;9(1):27–28.

Walter GB, Robert BD, Gerald MF, Joseph JI. (2004): Neurology in Clinical Practice Principles of Diagnosis and Management *Fourth Edition*-disorders of peripheral nerves.82,p2306.

Warner LE, Garcia CA, Lupski JR. (1999): Hereditary peripheral neuropathies: clinical forms, genetics, and molecular mechanisms. Annu Rev Med; 50:263-275.

Willison HJ. (2005): The immunobiology of Guillain–Barre syndromes. J Peripher Nerv Syst.; 10(2):94–112.

Wing P. Chan and Gin-Chung Liu (2002): MR Imaging of Primary Skeletal Muscle Diseases in Children. American Roentgen Ray Society. Pictorial Essay. AJR; Received 179:989-997; accepted after revision March 28, 2002.

Yo Okizuka, Yasuhiro Takeshima, Kyoko Itoh, etal (2008): Neuromuscul Disord;18:934-941.

Yoshikava T, Hayashi N, Yamamoto S et al. (2006): Brachial plexus injury: clinical manifestations, conventional imaging findings and the latest imaging techniques. Radiographics;26:133–143.

Younger DS (1999): Peripheral nerve pathology. In: Younger DS, editor. Motor disorders. Philadelphia: Lippincott Williams & Wilkins;81–92; with permission.)