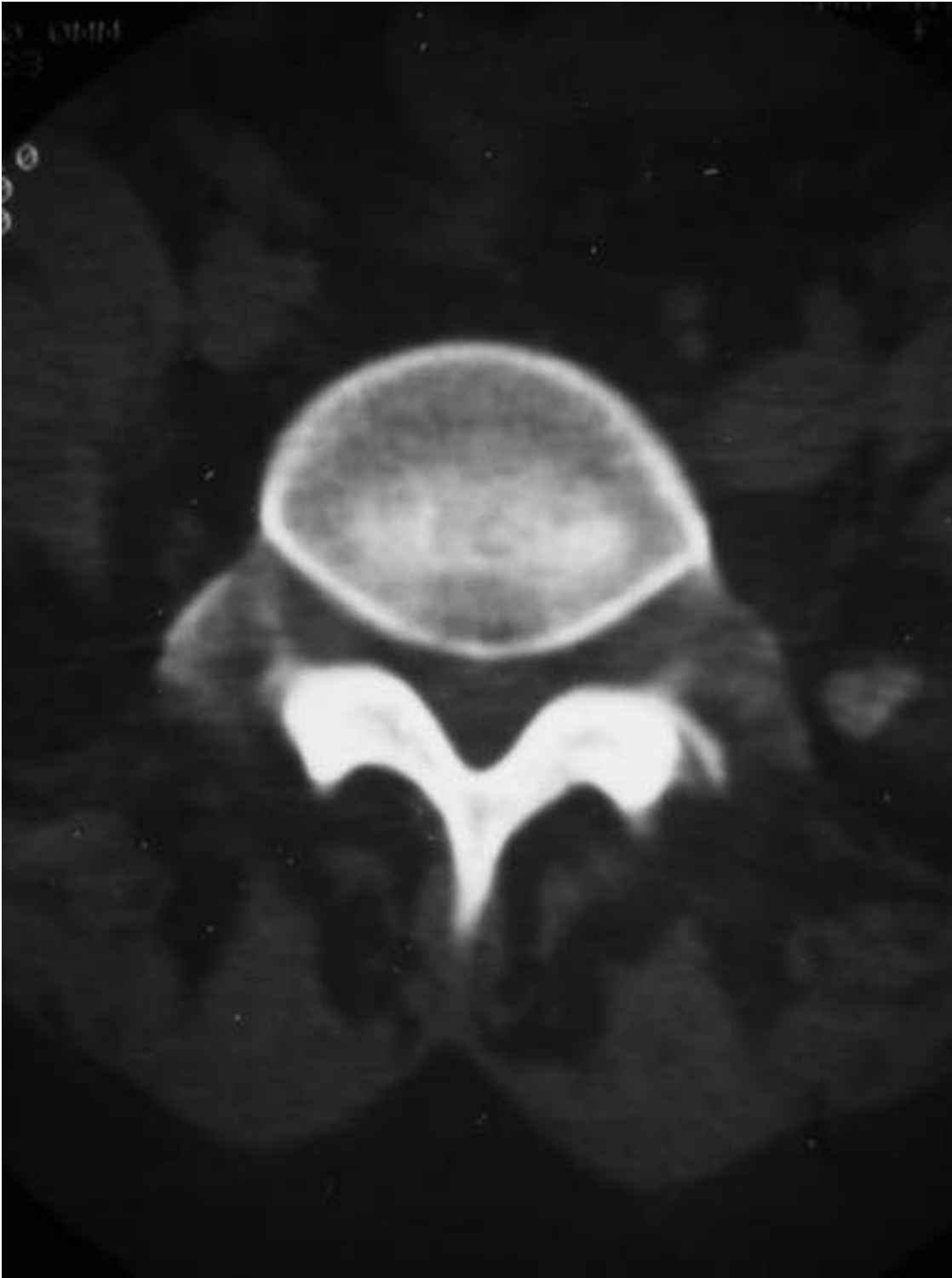


# Short case

Short case publication... Version 4.6 | Edited by professor Yasser Metwally | December 2010



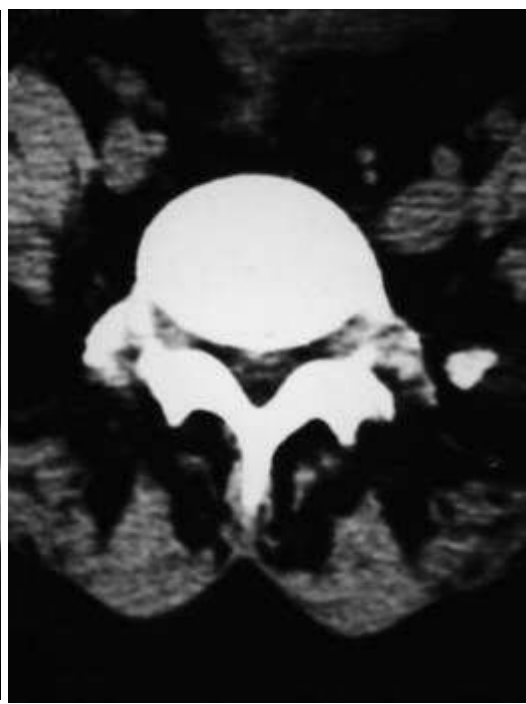
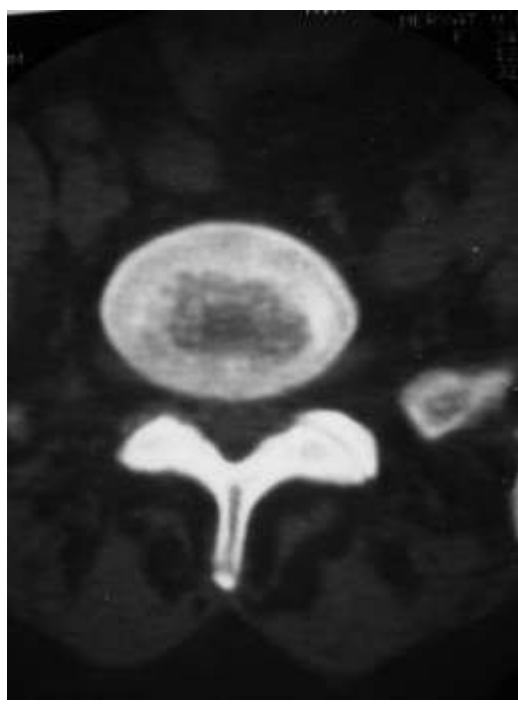
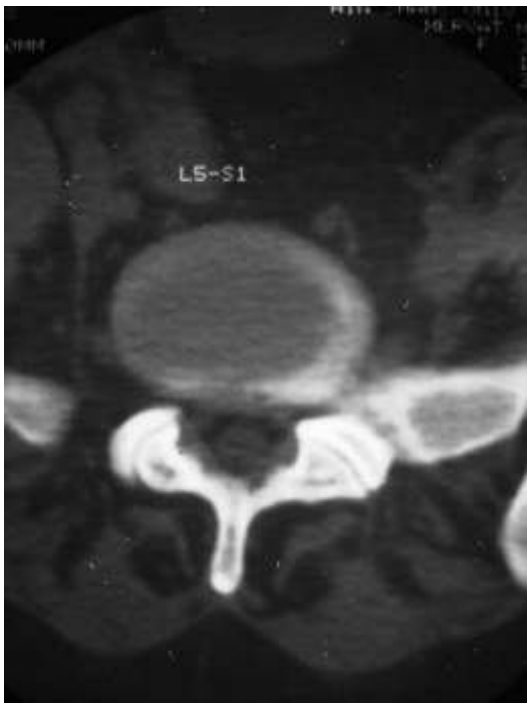
## Short case

Edited by  
Professor Yasser Metwally  
Professor of neurology  
Ain Shams university school of medicine  
Cairo, Egypt

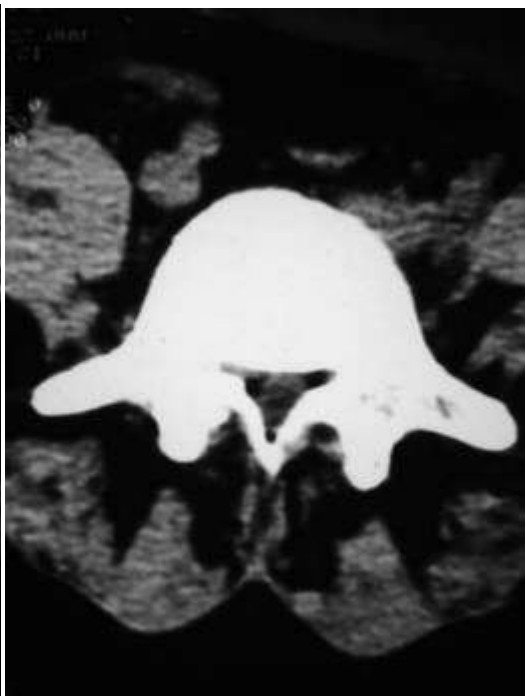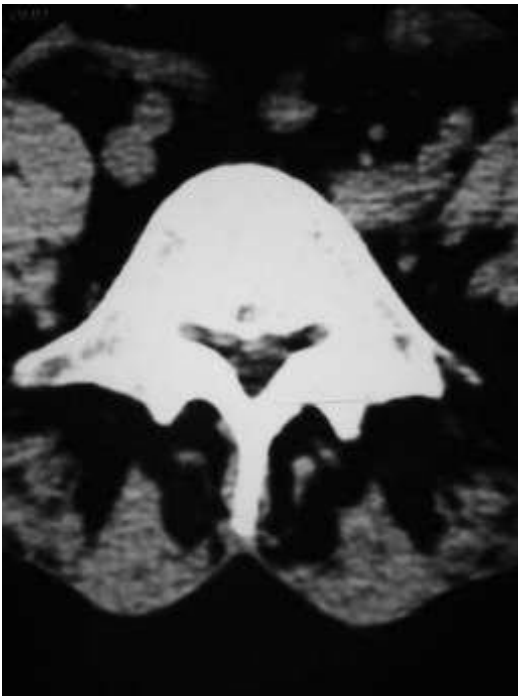
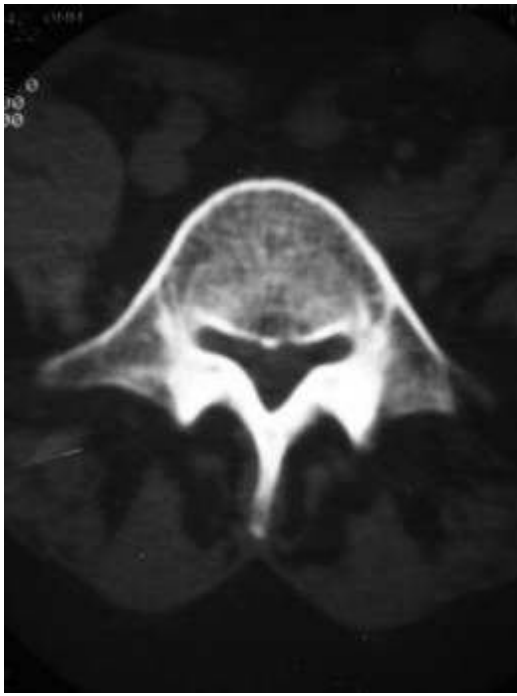
Visit my web site at:  
<http://yassermetwally.com>

33 Years old male patient presented clinically with neurogenic claudication of the cauda equina. Clinical examination revealed depression of the left ankle reflex.

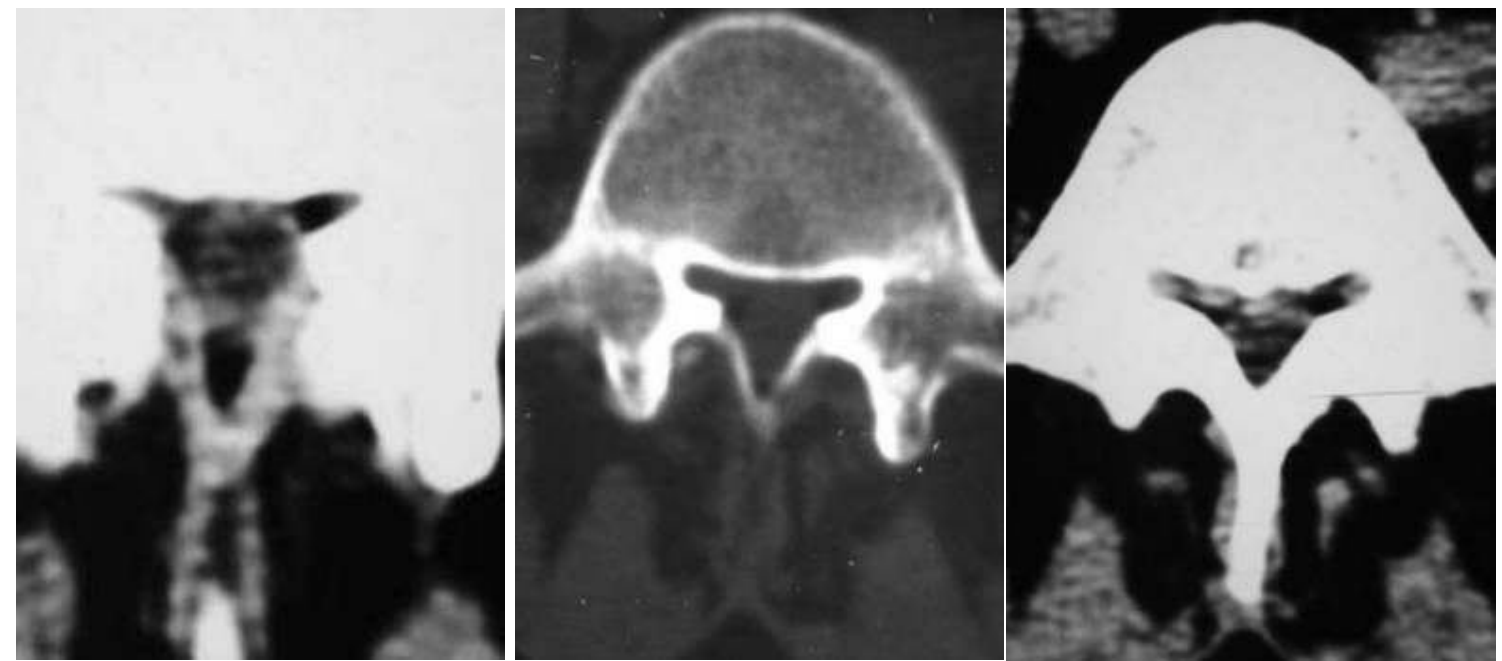
**DIAGNOSIS:** CONSTITUTIONAL LUMBAR CANAL STENOSIS



**Figure 1. Plain CT scan lumbar spine showing bony stenosis of the lumbar canal (antero-posterior diameter is 11.5 CM). Notice mild annular bulging, articular fact pathology (asymmetric orientation, medial osteophytosis, and reduction of the synovial joint space). The lumbar canal is trefoil in shape.**



**Figure 2. Plain CT scan lumbar spine showing bony stenosis of the lumbar canal (antero-posterior diameter is 11.5 CM). Notice articular fact pathology (asymmetric orientation, medial osteophytosis, and reduction of the synovial joint space and some facet hypertrophy). The lumbar canal is trefoil in shape.**



**Figure 3. Plain CT scan lumbar spine showing bony stenosis of the lumbar canal (antero-posterior diameter is 11.5 CM). Notice ligamentum flavum hypertrophy. The lumbar canal is trefoil in shape.**

### References

1. Metwally, MYM: Textbook of neurimaging, A CD-ROM publication, (Metwally, MYM editor) WEB-CD agency for electronic publishing, version 11.4a October 2010

### Addendum

- ◆ A new version of short case is uploaded in my web site every week (every Saturday and remains available till Friday.)
- ◆ To download the current version follow the link "<http://pdf.yassermetwally.com/short.pdf>".
- ◆ You can download the long case version of this short case during the same week from: <http://pdf.yassermetwally.com/case.pdf> or visit web site: <http://pdf.yassermetwally.com>
- ◆ To download the software version of the publication (crow.exe) follow the link: <http://neurology.yassermetwally.com/crow.zip>
- ◆ At the end of each year, all the publications are compiled on a single CD-ROM, please contact the author to know more details.
- ◆ Also to view a list of the previously published case records follow the following link: (<http://wordpress.com/tag/case-record/>) or click on it if it appears as a link in your PDF reader
- ◆ To inspect the patient's full radiological study, click on the attachment icon (the paper clip icon in the left pane) of the acrobat reader then double click on the attached file
- ◆ [Click here](#) to download the long case version of this short case in PDF format